



CONGRÈS 2021

**Imagerie Appliquée  
à la Pratique Pneumologique**



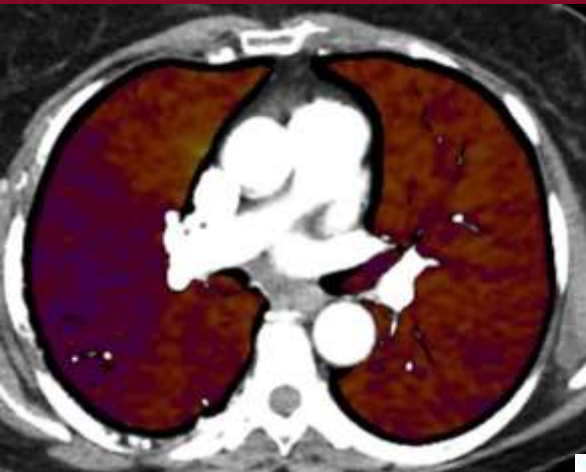17 & 18  
SEPTEMBRE 2021  
TOULOUSE



**AP-HP. Nord  
Université  
de Paris**

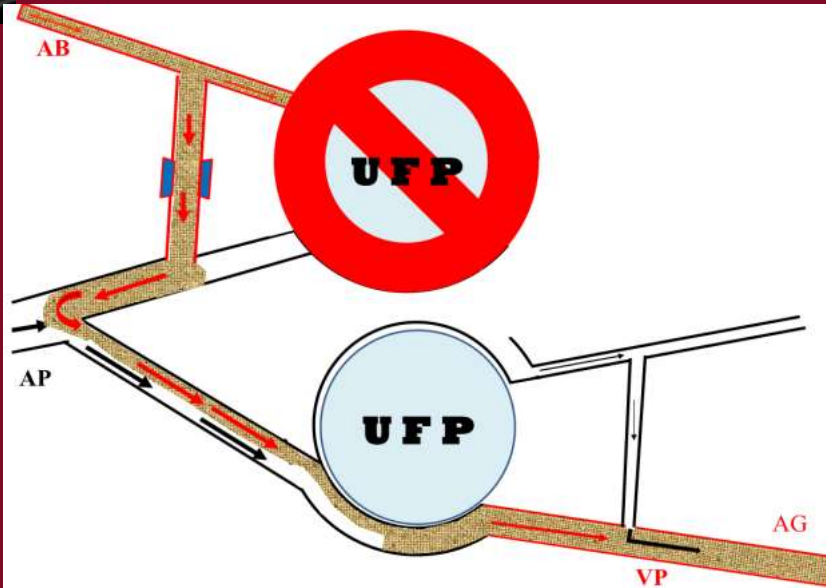


Université de Paris



# La pseudo embolie pulmonaire:

## Ne pas s'y prendre

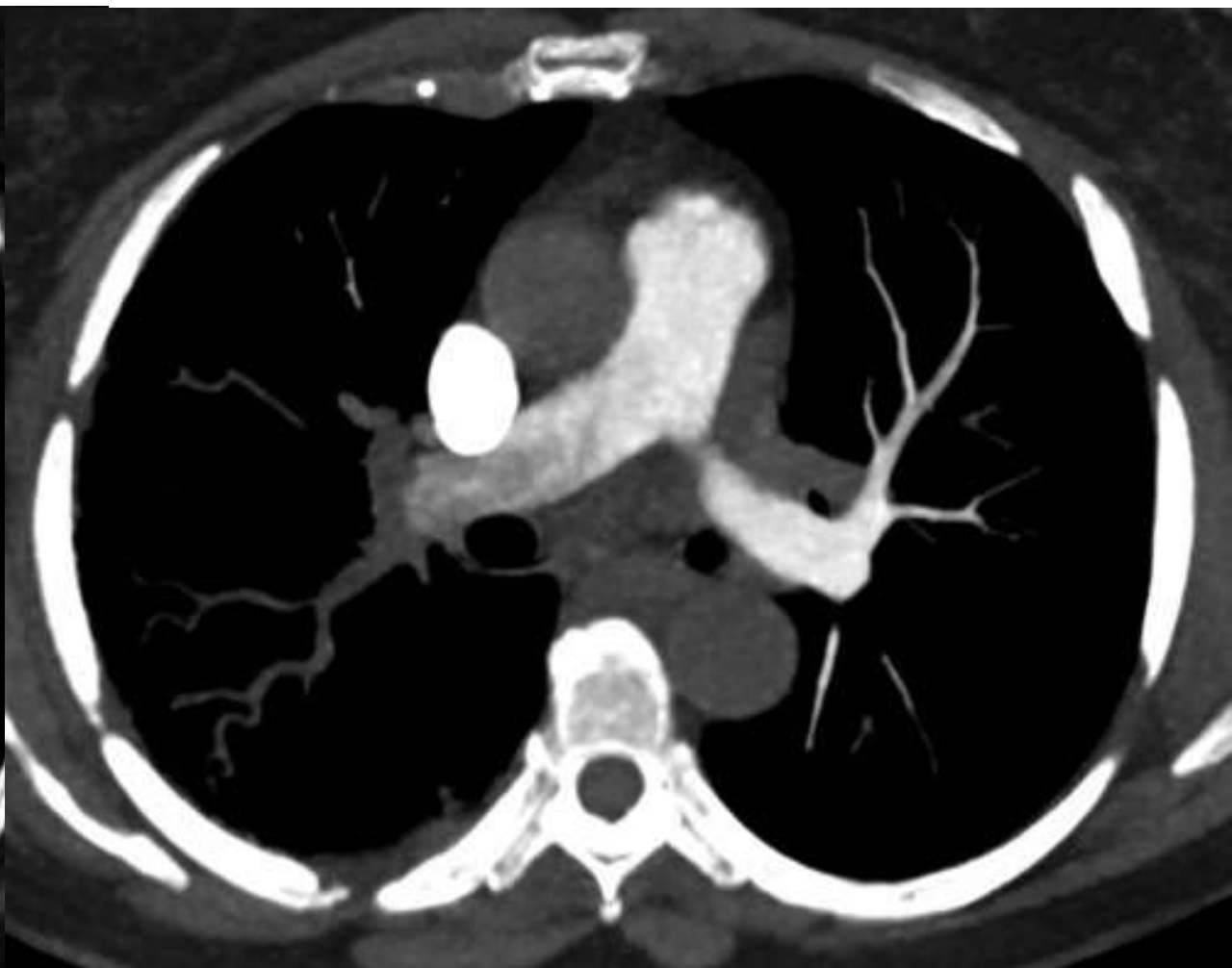
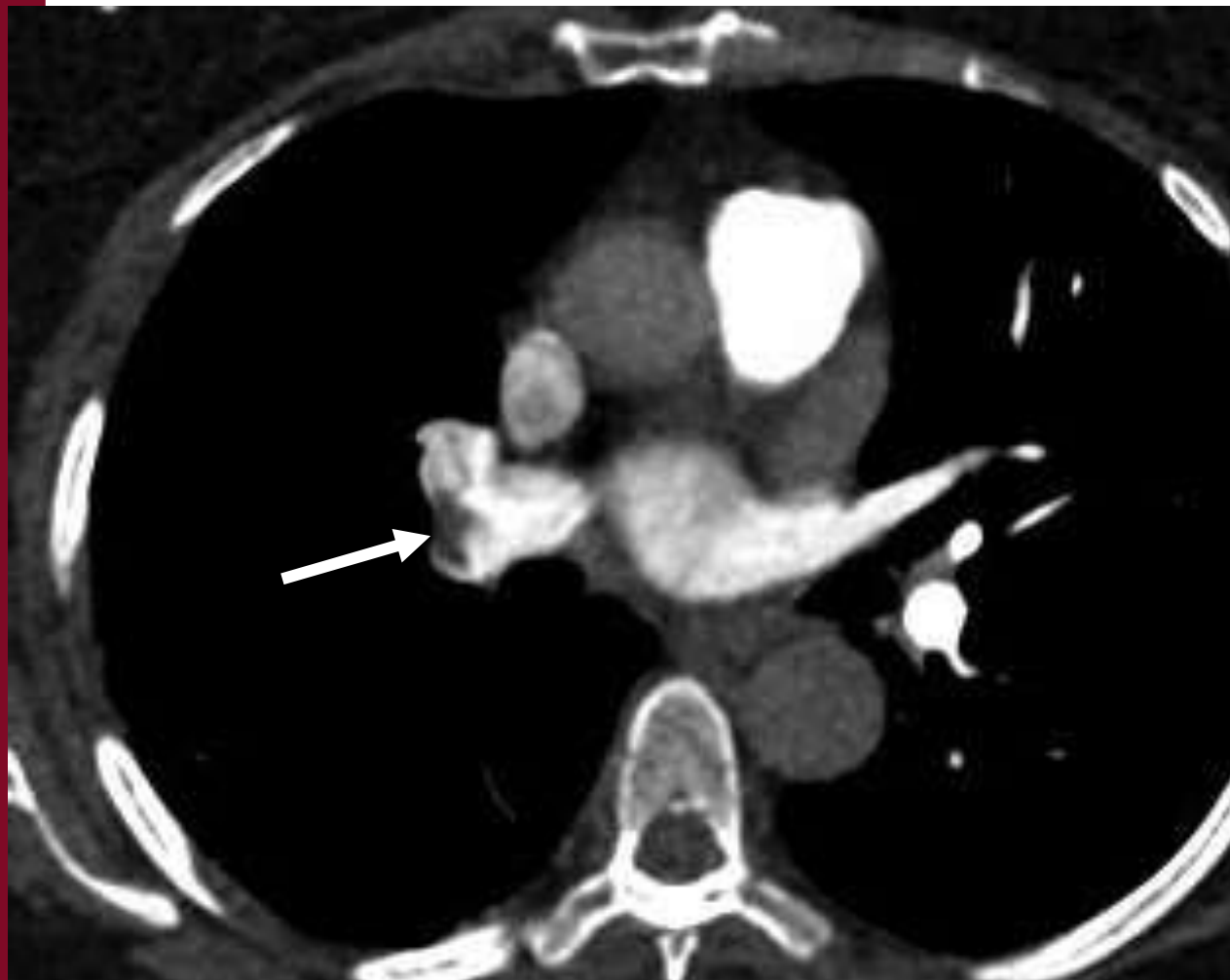
*Pr. Antoine KHALIL*

*Pr. Marie-Pierre DEBRAY*

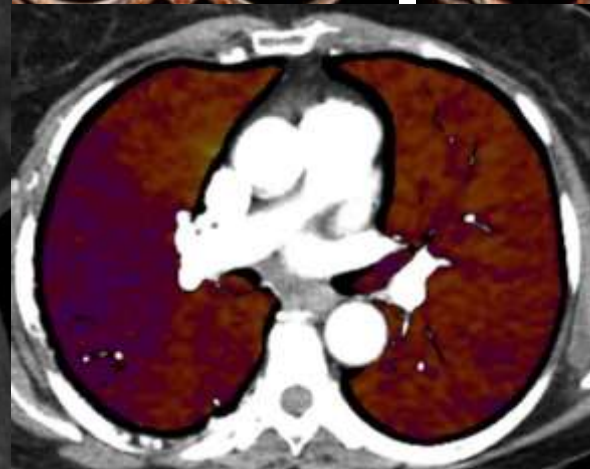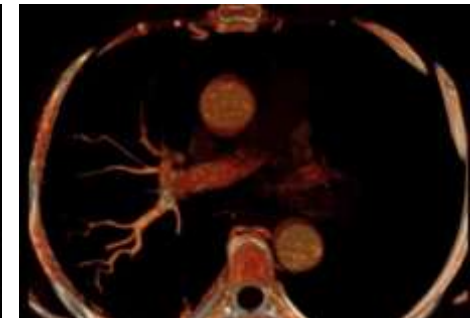
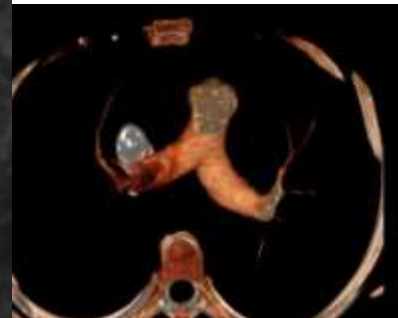
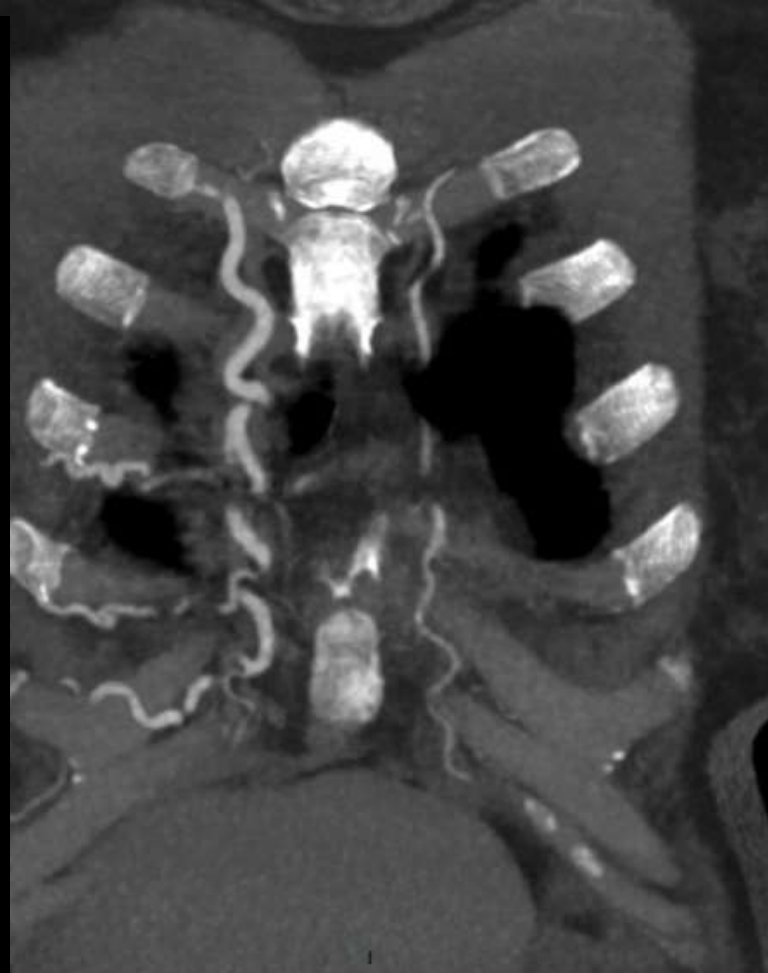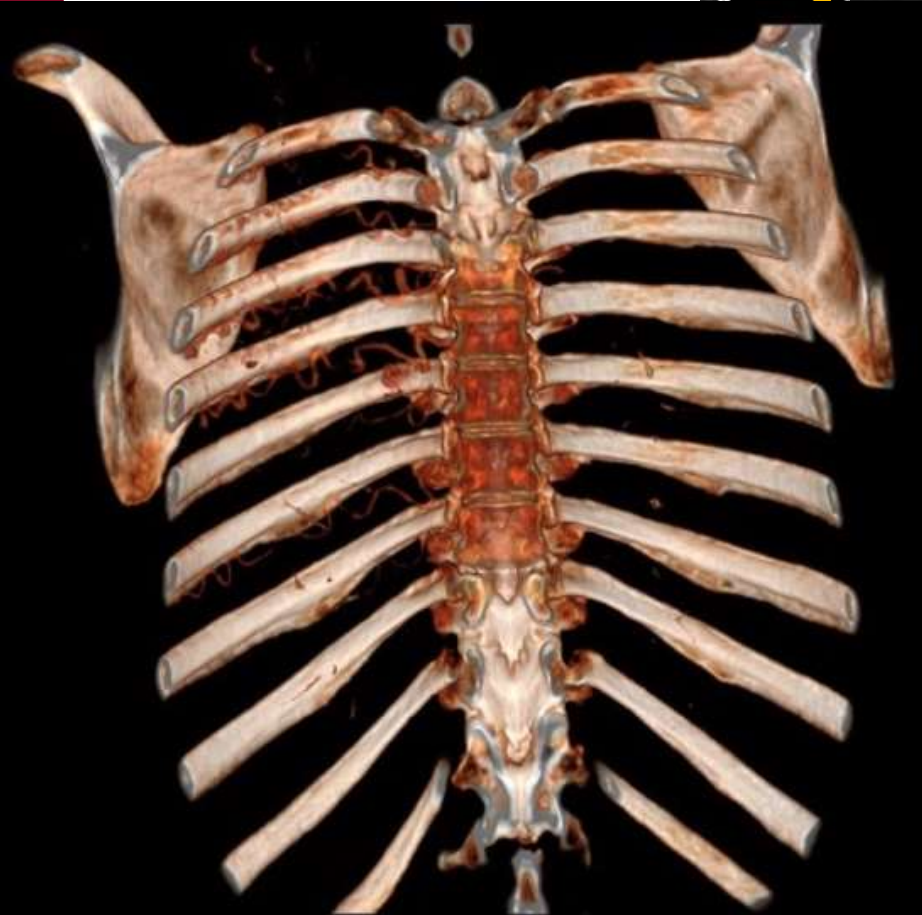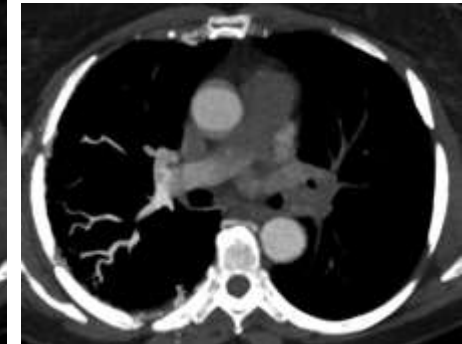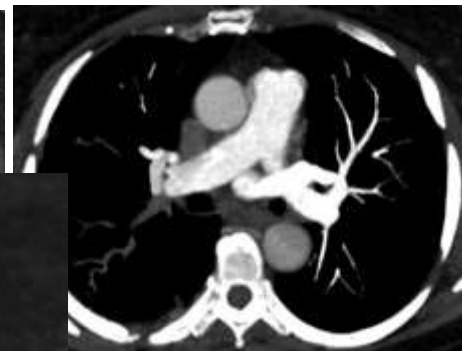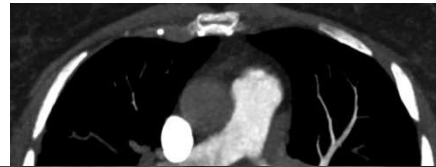
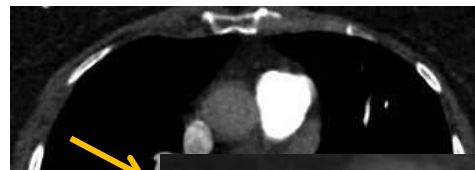*APHP-NORD, UNIVERSITÉ DE PARIS  
HÔPITAL BICHAT-CLAUDE BERNARD*

**Femme de 52 ans présentant des douleurs thoraciques droite avec essoufflement, un angioTDM à la recherche d'EP a été effectué**



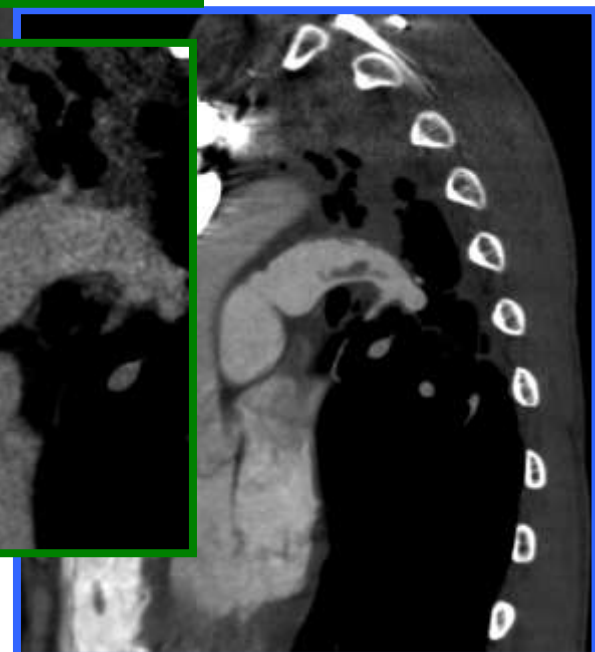
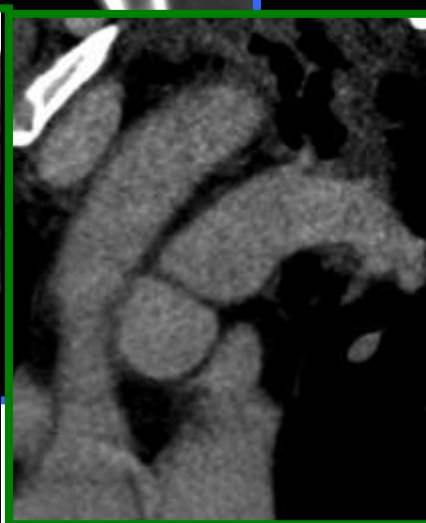
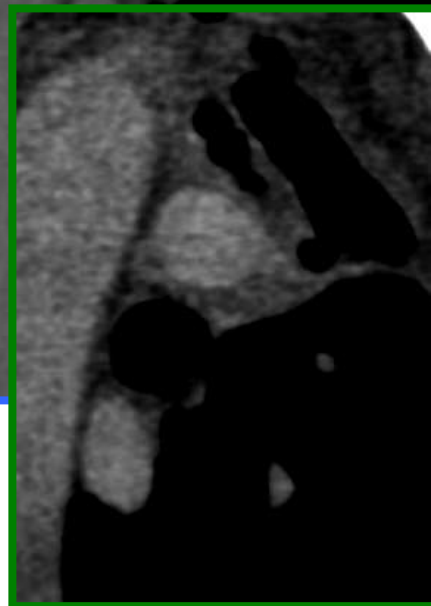
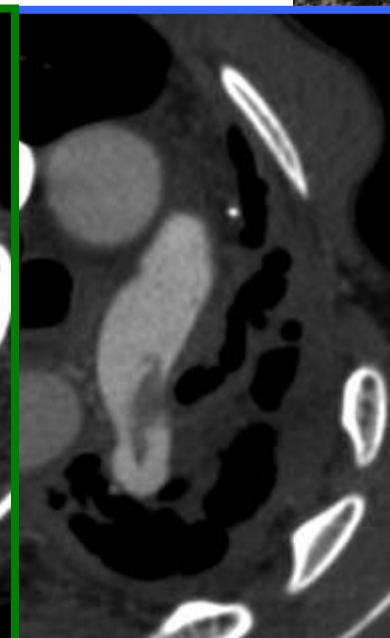
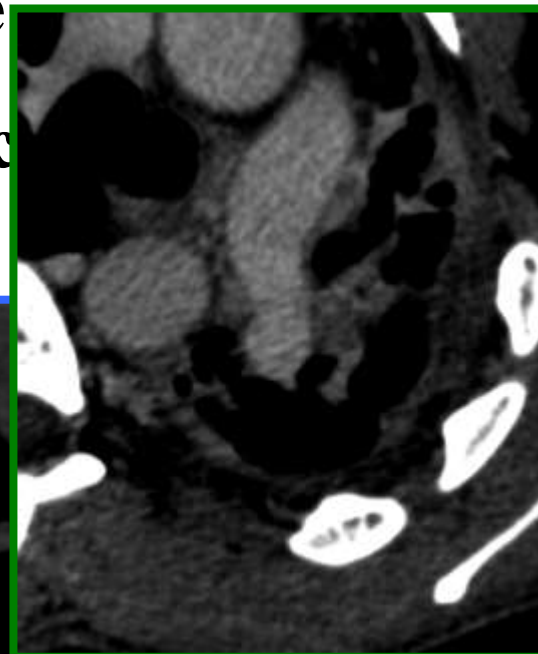
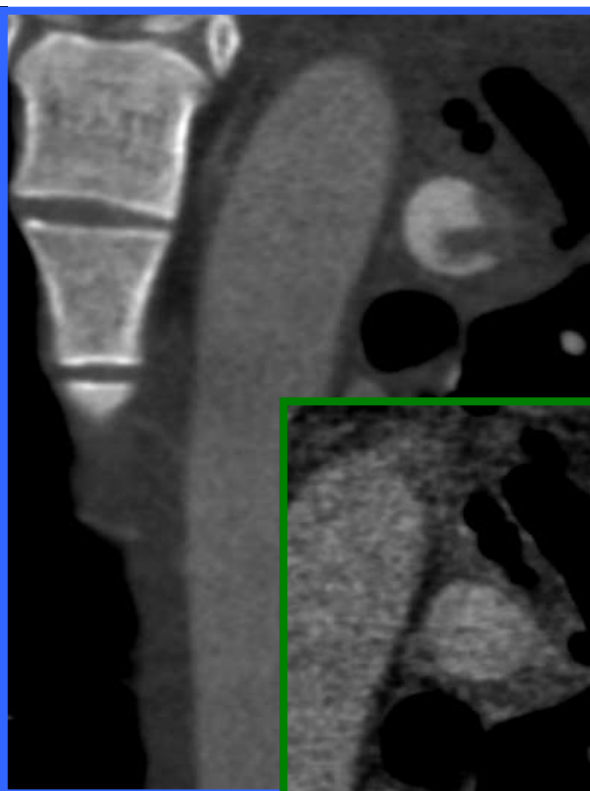
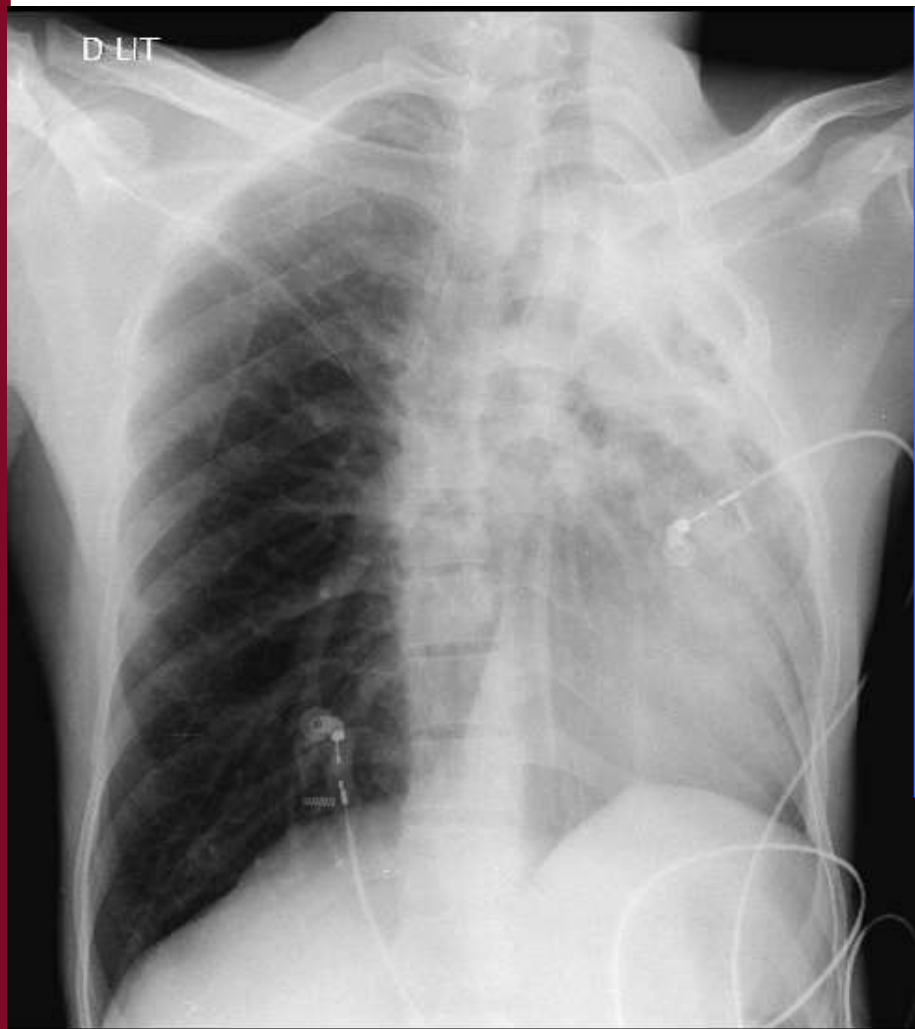
# Lacune artérielle pulmonaire ou asynchronisme de flux ?

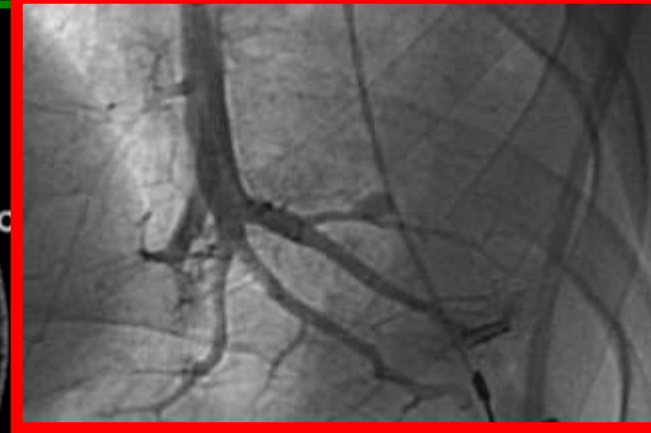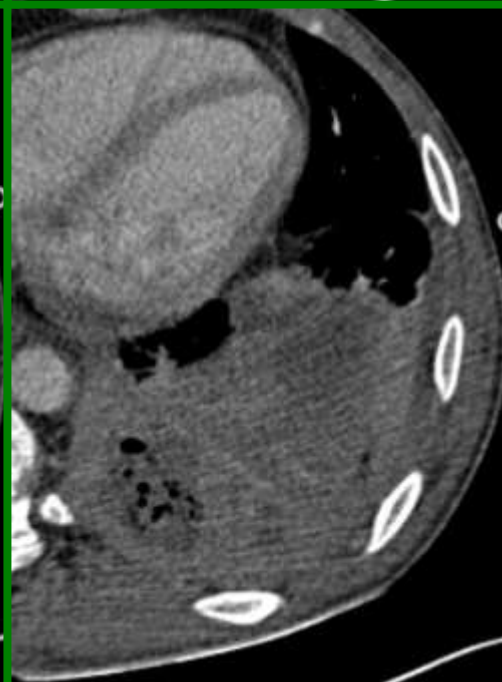
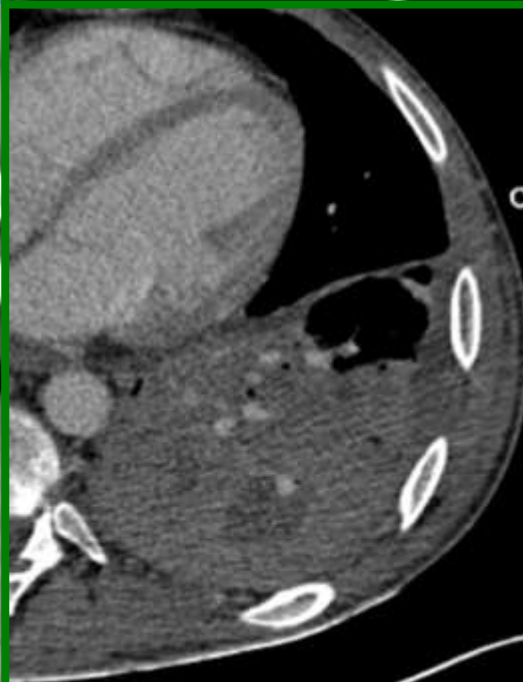
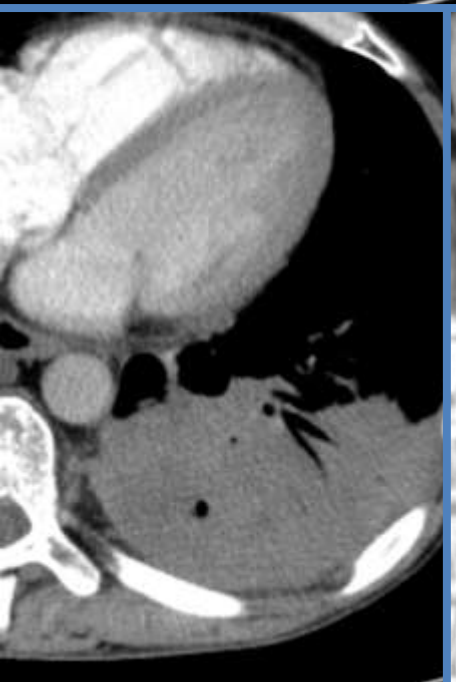
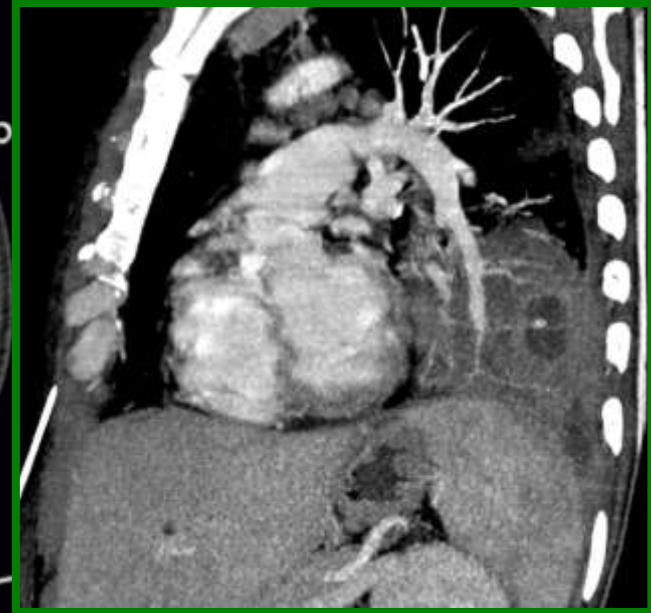
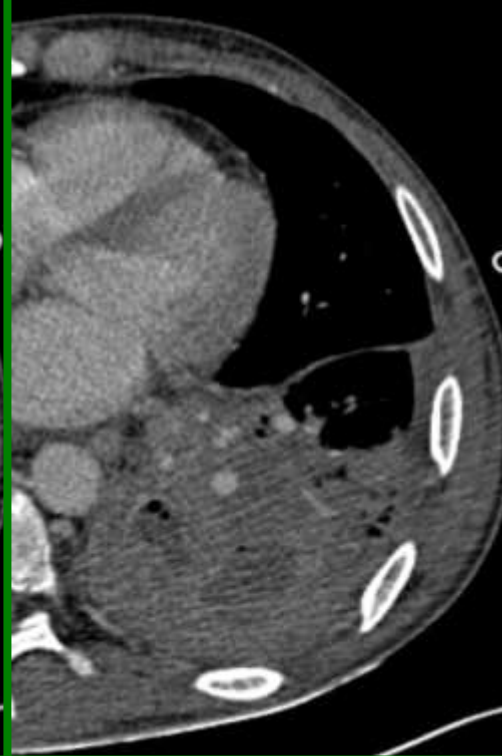
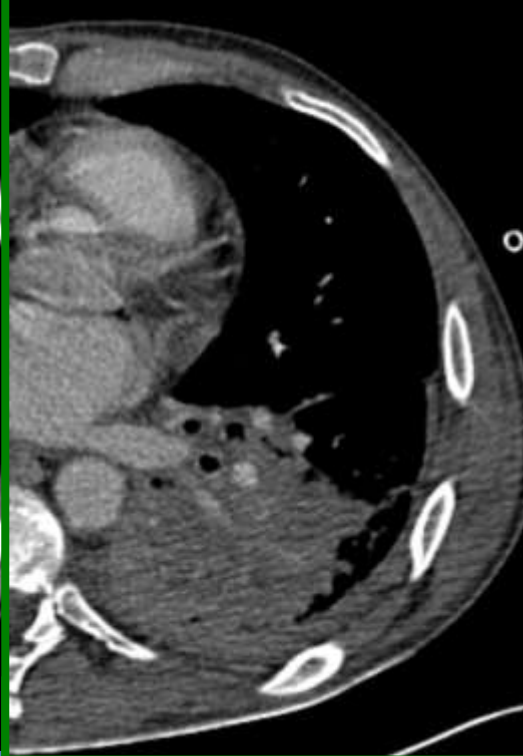
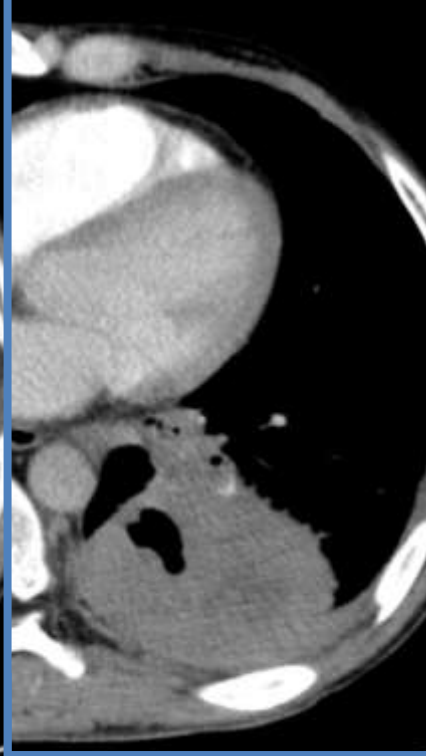
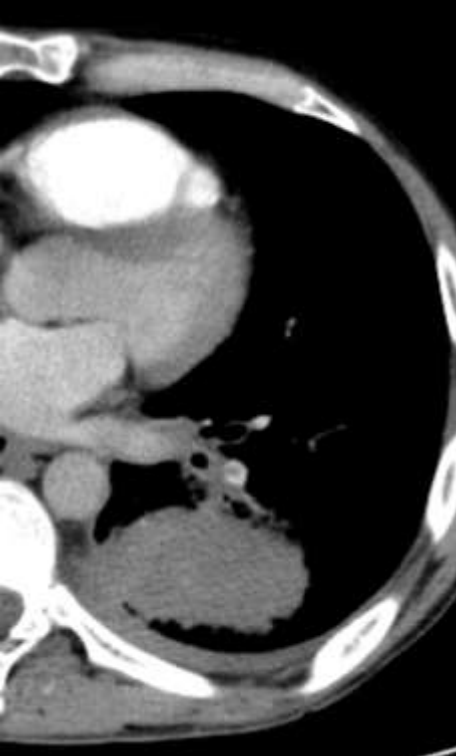
Acquisition volumique 4D intermittente en respiration libre sur 16 cm pendant 20 sec; PDL= 164 mGy.cm



**Homme de 26 ans, aggravation d'une dyspnée**

**Notion de tuberculose durant l'enfance, suspic**





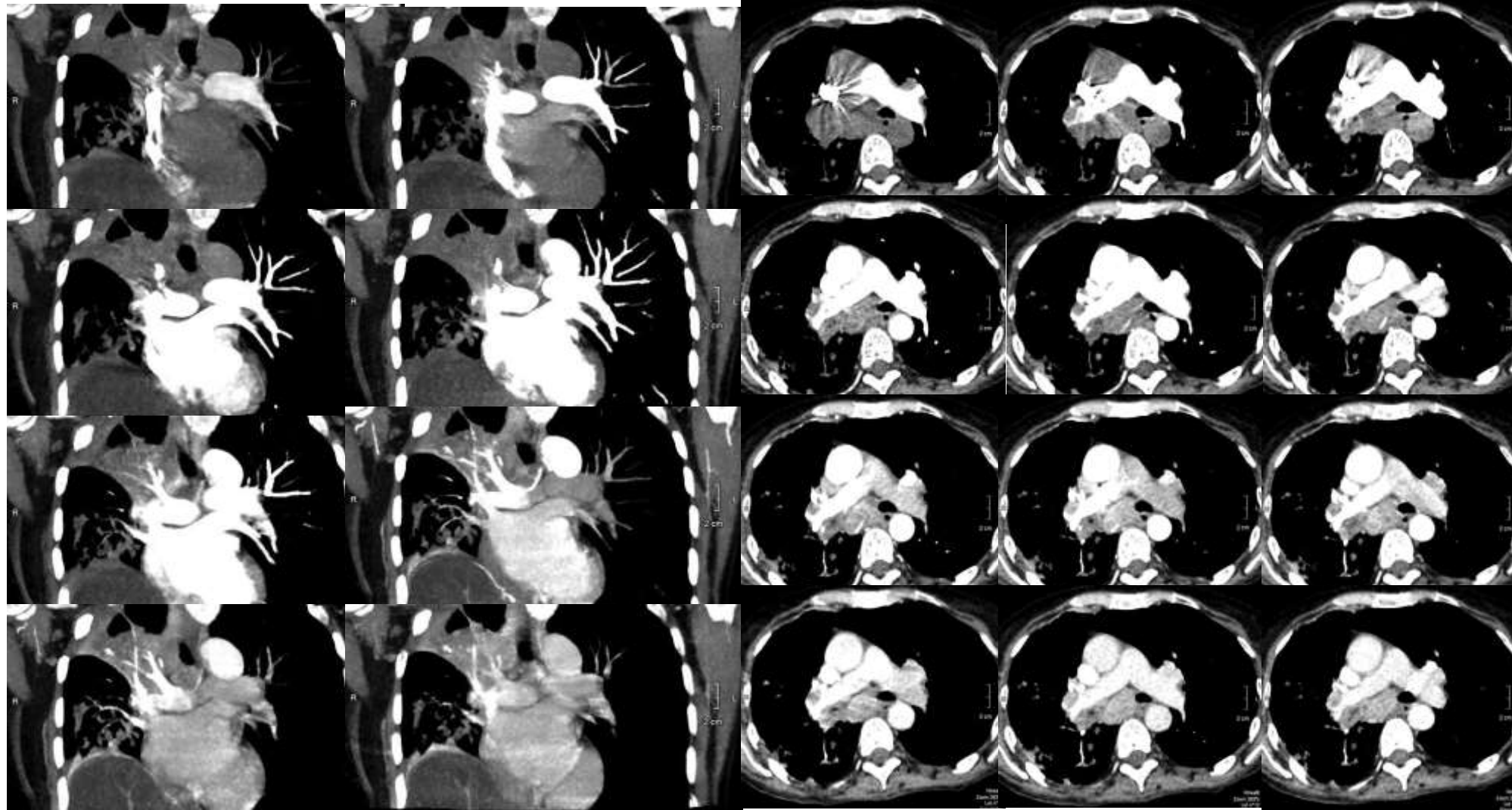
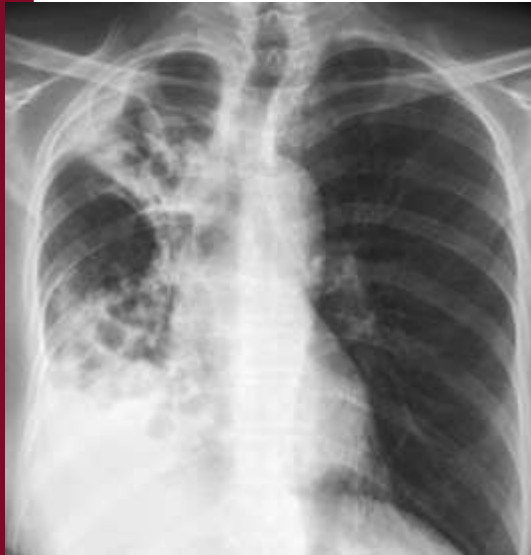# Hémoptysie-séquelles de tuberculose

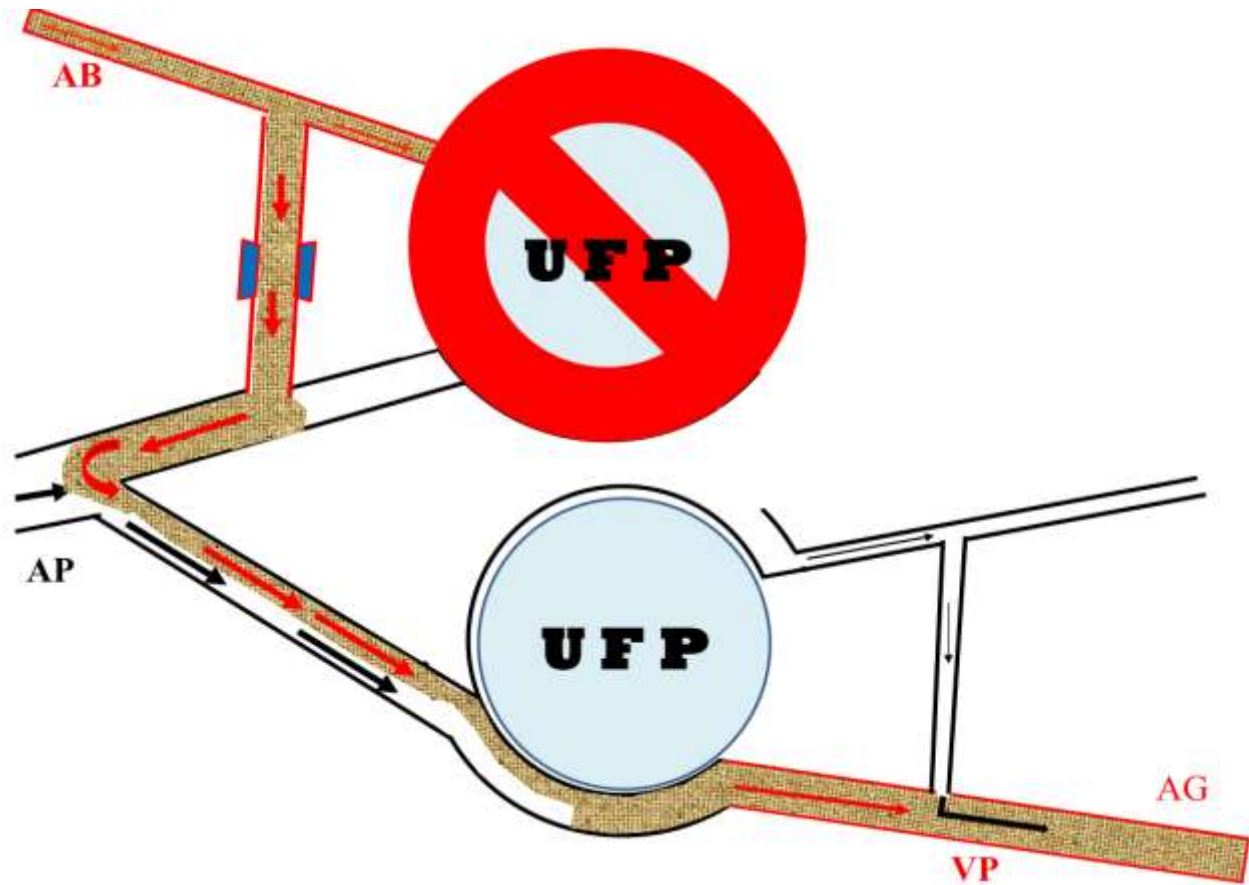
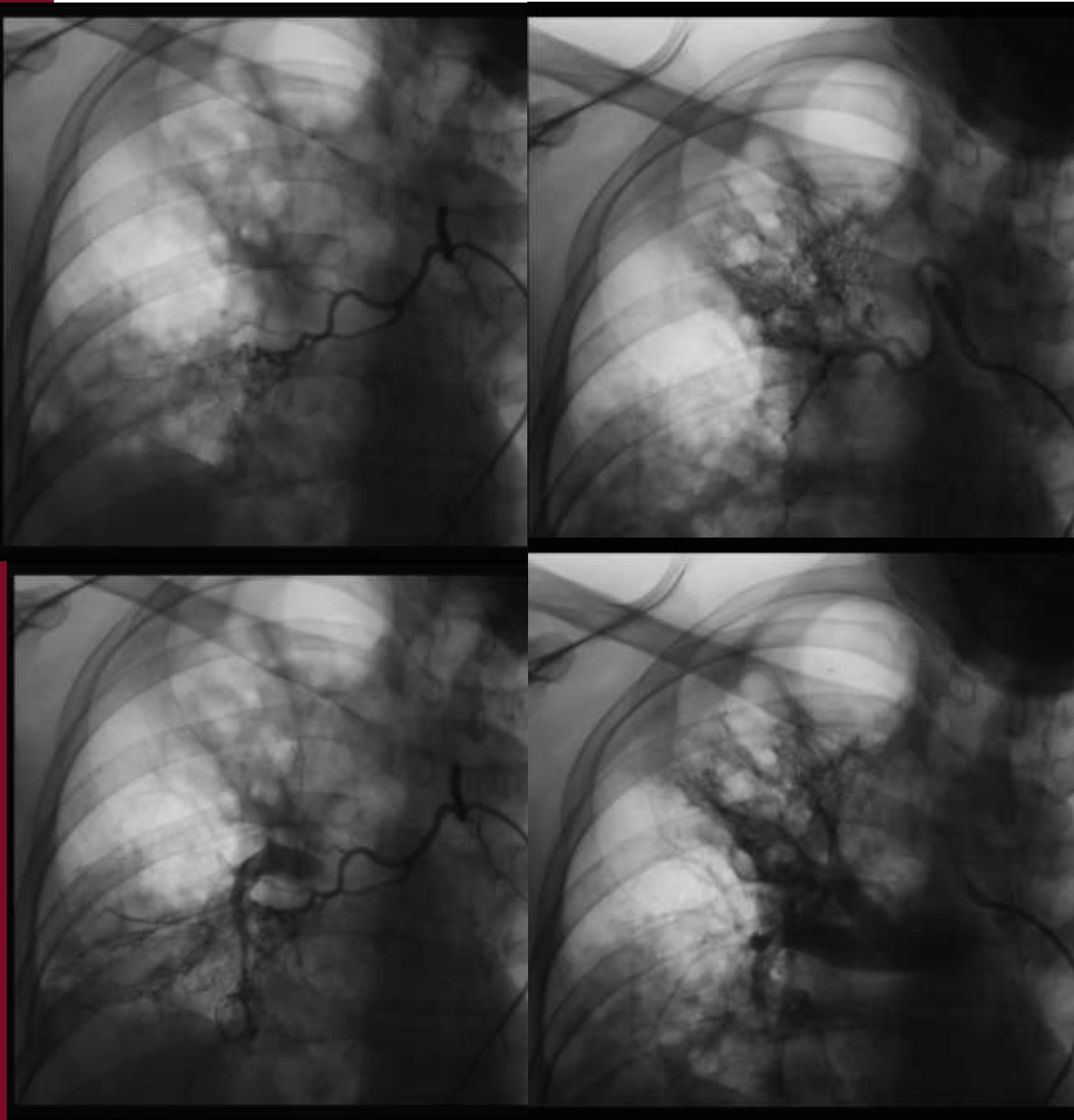


Acquisition volumique 4D intermittente en respiration douce sur 16 cm pendant 30 sec

Recalage des séries avant calcul des cartographies de perfusion

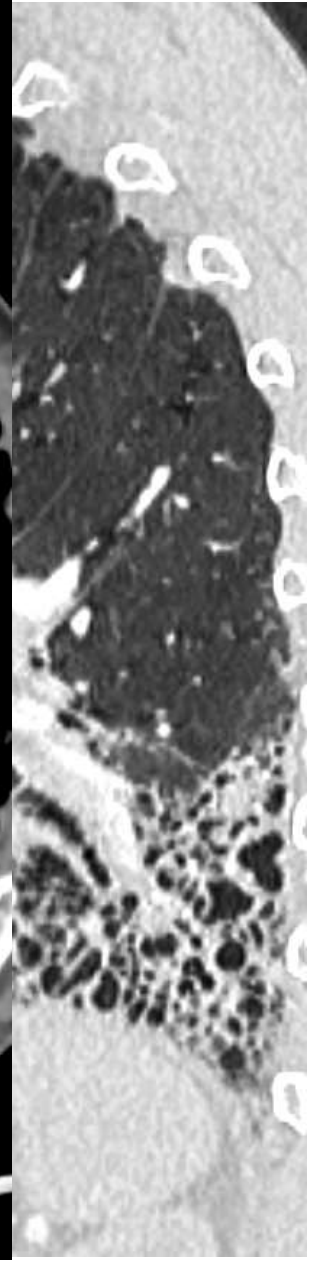
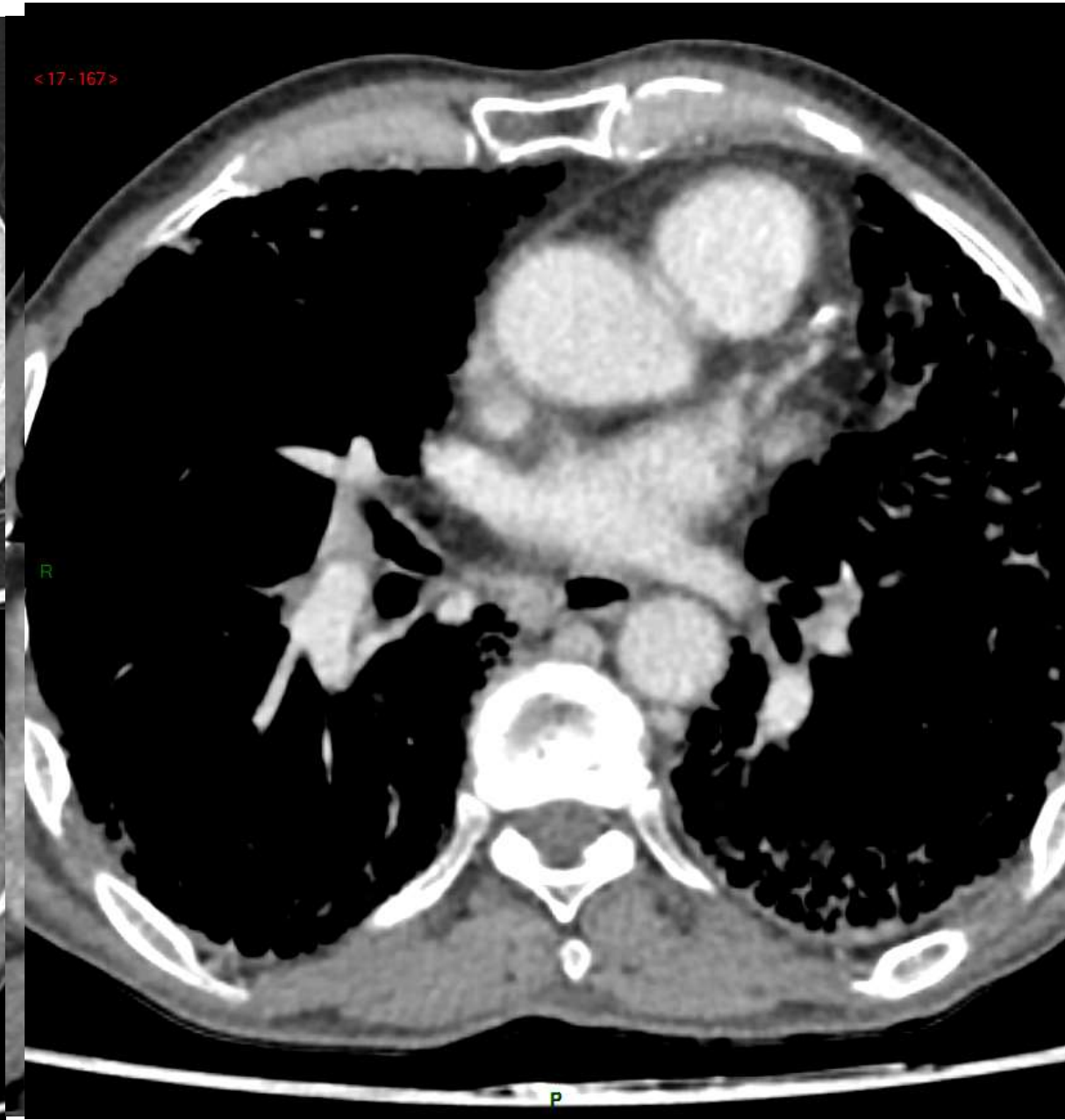
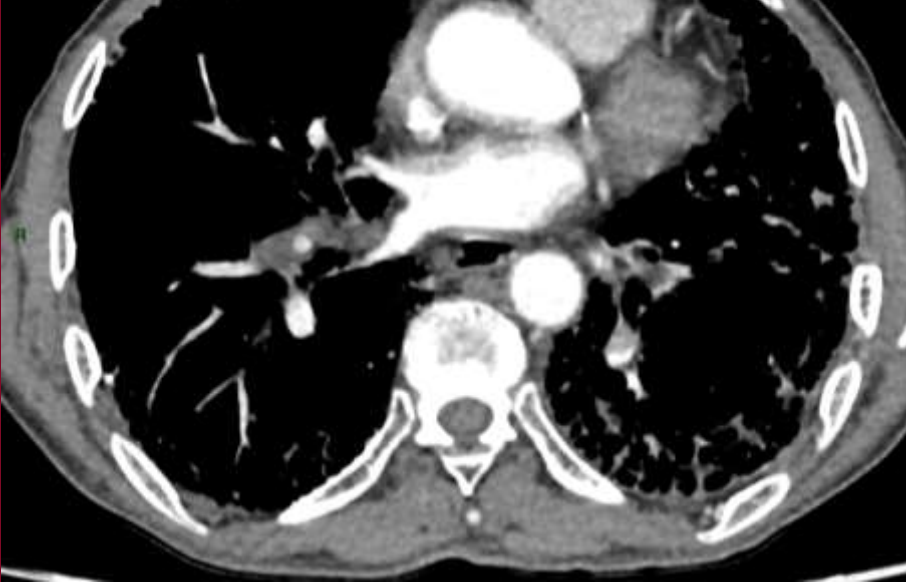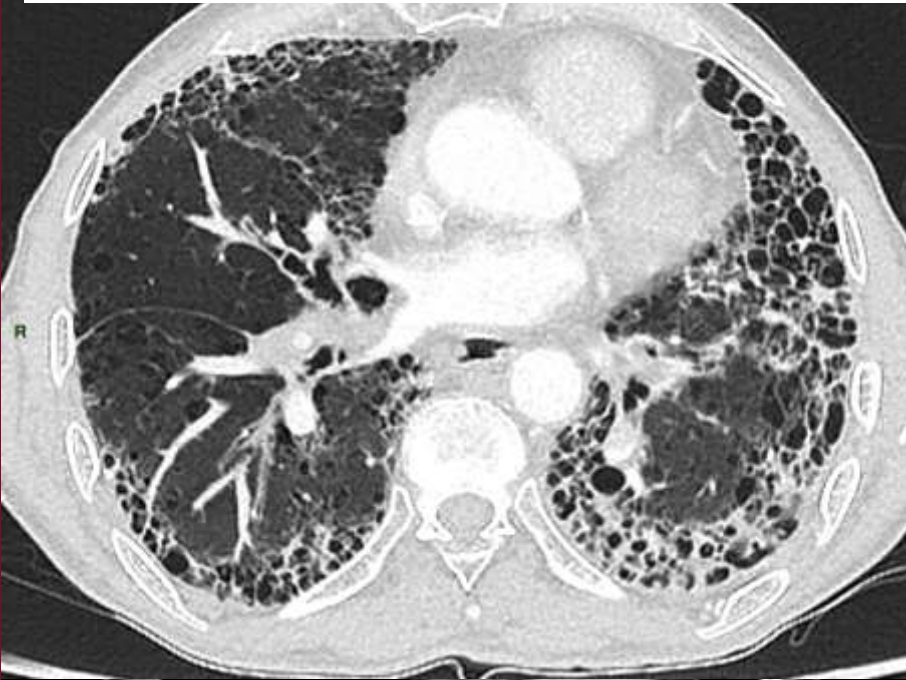PDL= 246 mGy.cm





Homme de 59 ans est hospitalisé pour une dyspnée avec FPI.

Angio-TDM éliminer une EP







CONGRÈS 2021

**Imagerie Appliquée  
à la Pratique Pneumologique**



**AP-HP. Nord  
Université  
de Paris**

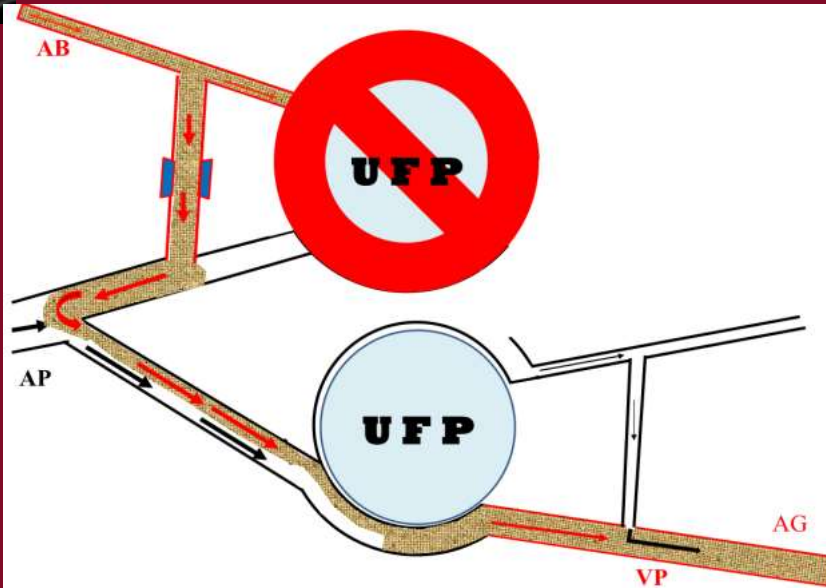


Université de Paris



# La pseudo embolie pulmonaire:

## Ne pas s'y prendre



*Pr. Antoine KHALIL*

*Pr. Marie-Pierre DEBRAY*

*APHP-NORD, UNIVERSITÉ DE PARIS  
HÔPITAL BICHAT-CLAUDE BERNARD*