Le nodule pulmonaire

Sébastien Bommart

CHU Montpellier

Le nodule pulmonaire

- Problématique
- Démarche diagnostique
  - Suivi oncologique
  - Nodule fortuit
- Surveillance: Recommandations 2017

Problématique

- Prévalence TDM chez le fumeur: 25 à 50 %
- > 95% bénins
- ↗ détection (dépistage)

Recent Trends in the Identification of Incidental Pulmonary Nodules

Michael K. Gould[1], Tania Tang[1], In-Lu Amy Liu[1], Janet Lee[1], Chengyi Zheng[1], Kim N. Danforth[1], Anne E. Kosco[2], Jamie L. Di Fiore[3], and David E. Suh[4]

AJRCCM 2015

Analyse épidémiologique des pratiques aux USA (≠ protocole de dépistage)

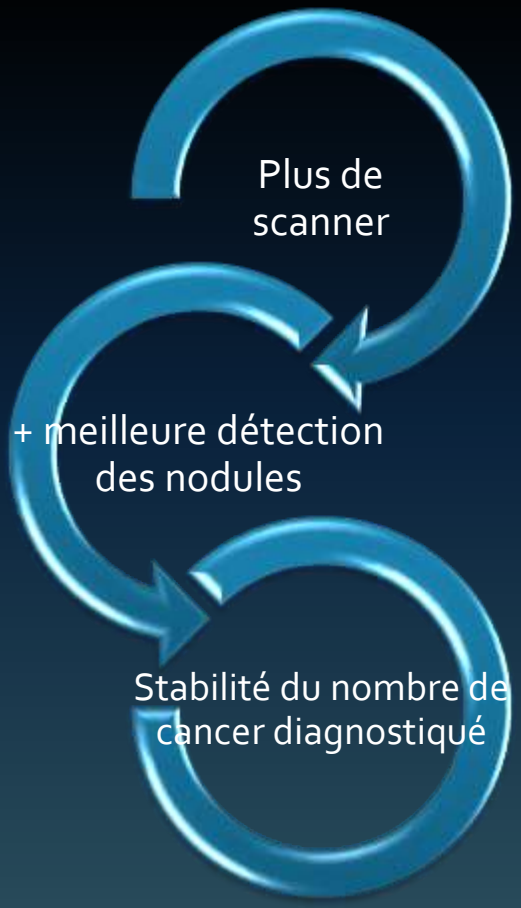

Démarche diagnostique

- 3 situations distinctes:

- **Découverte fortuite**
- **Dépistage**
- **Suivi oncologique**

Le nodule pulmonaire

- Problématique
- Démarche diagnostique
  - Suivi oncologique
  - Nodule fortuit
- Surveillance: Recommandations 2017

Suivi oncologique

RECIST 1.1

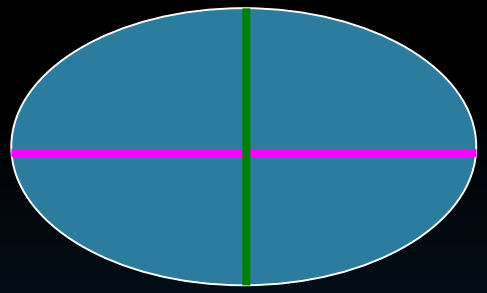

Lésions mesurables

- Mesure du plus grand axe de la lésion (sauf ganglion)
- Nombre : maximum 5 cibles par patient
  maximum 2 cibles par organe
- Somme des lésions cibles = somme des plus grands diamètres

Suivi oncologique

RECIST 1.1

- Réponse complète: disparition de toutes les lésions
- Maladie en progression: progression NON EQUIVOQUE des lésions
- Maladie stable ou réponse incomplète: persistance d'une ou plusieurs lésions

Le nodule pulmonaire

- Problématique
- Démarche diagnostique
  - Suivi oncologique
  - Nodule fortuit
- Surveillance: Recommandations 2017

Découverte fortuite

- **Démarche diagnostique**

Recommendations for Measuring Pulmonary Nodules at CT: A Statement from the Fleischner Society[1]

Radiology

Radiology: Volume 285: Number 2—November 2017

Découverte fortuite

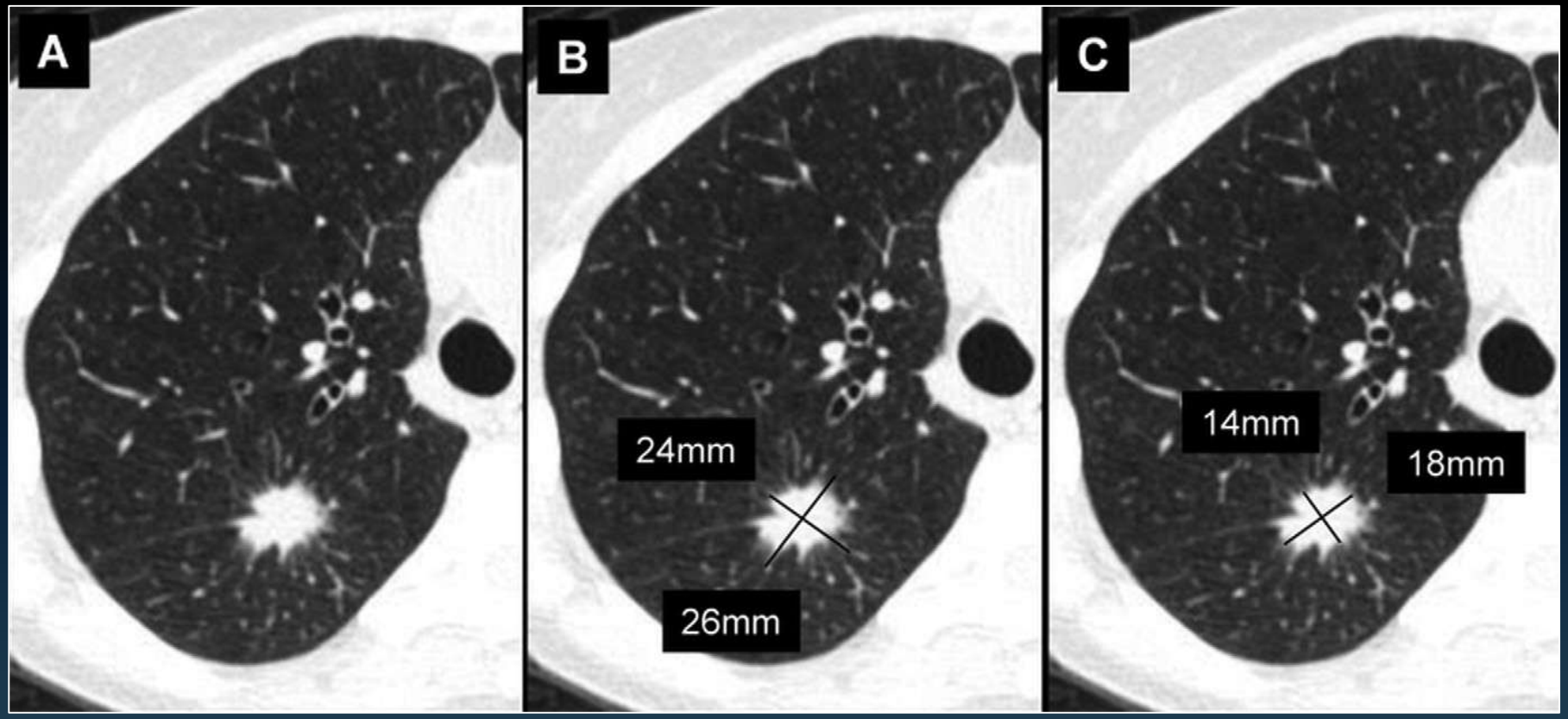

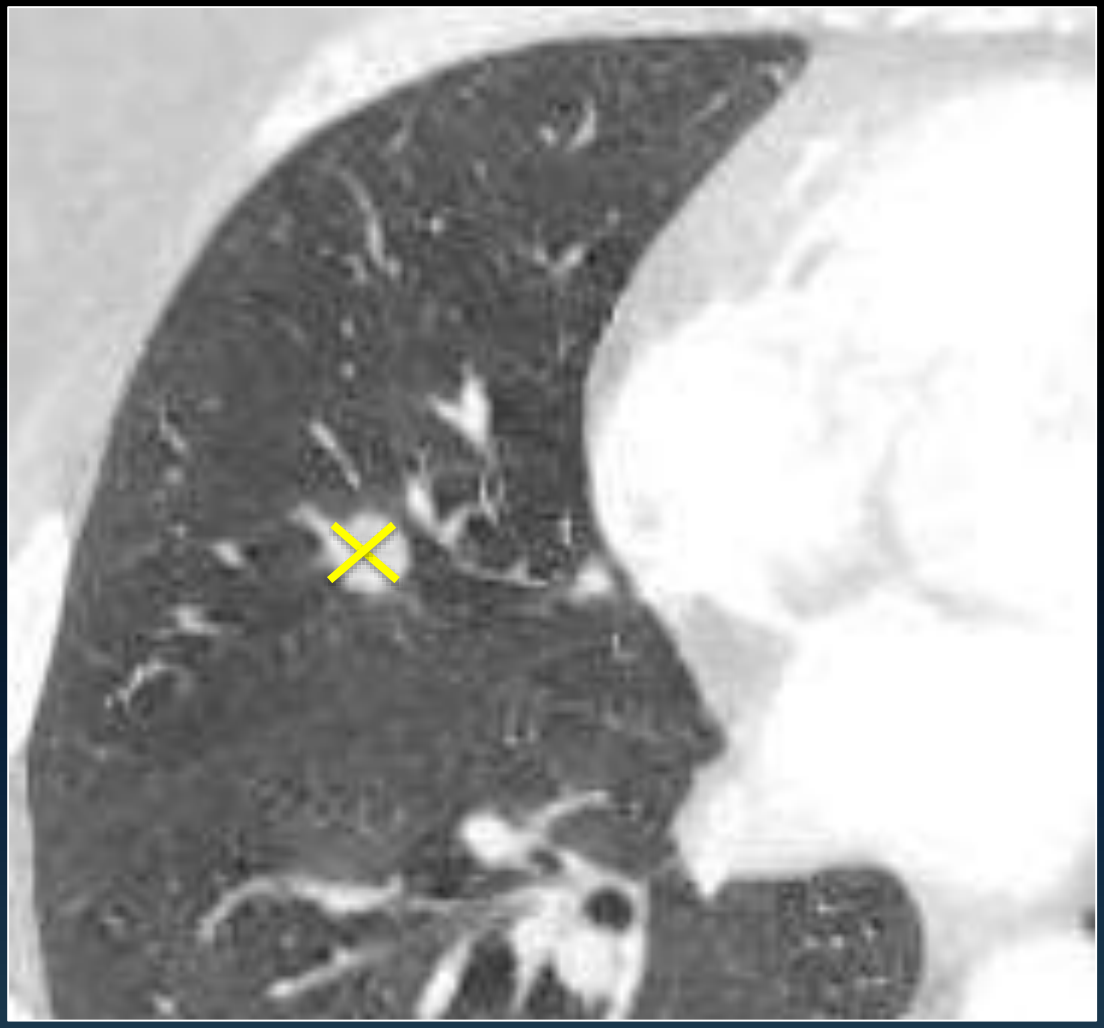

7 X9 mm

Kovalchik SA. Targeting of low-dose CT screening according to the risk of lung-cancer death. N Engl J Med 2013

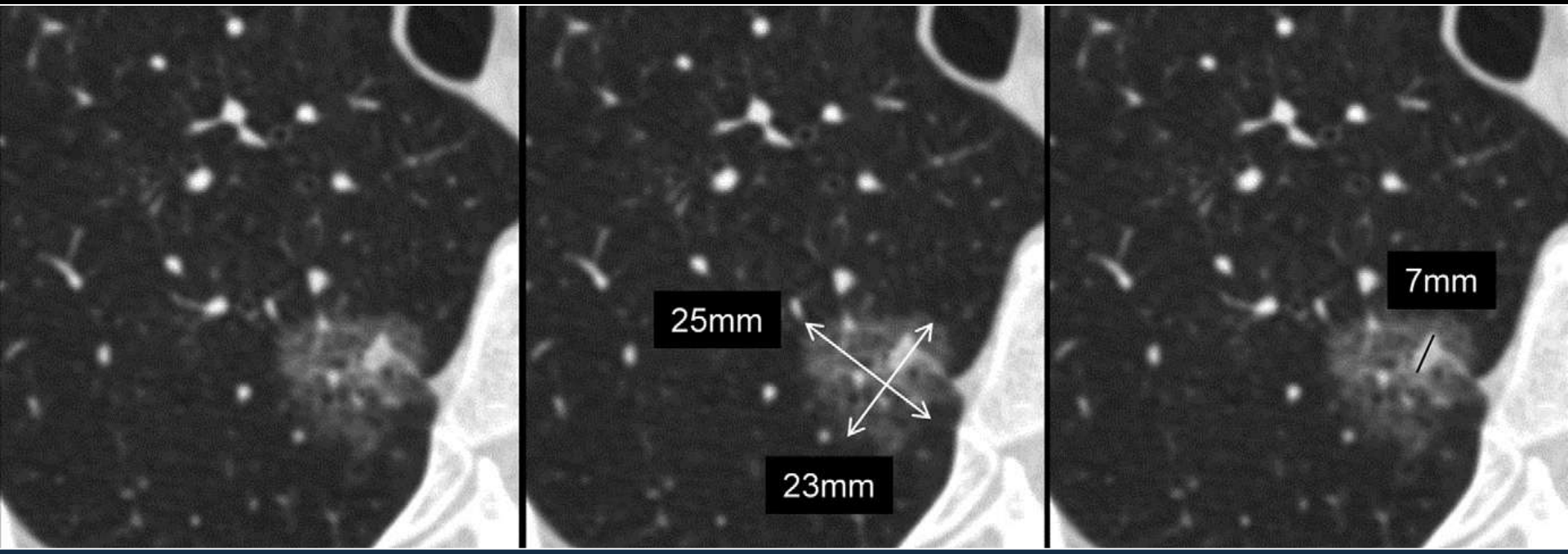
25mm
23mm
7mm

Découverte fortuite

- **Démarche diagnostique**
  - Faux nodules et nodules transitoires
  - Images bénignes
  - Lésions certainement malignes
  - Lésions indéterminées

Faux nodules et nodules transitoires

♀ 49 ans – maladie de Behcet

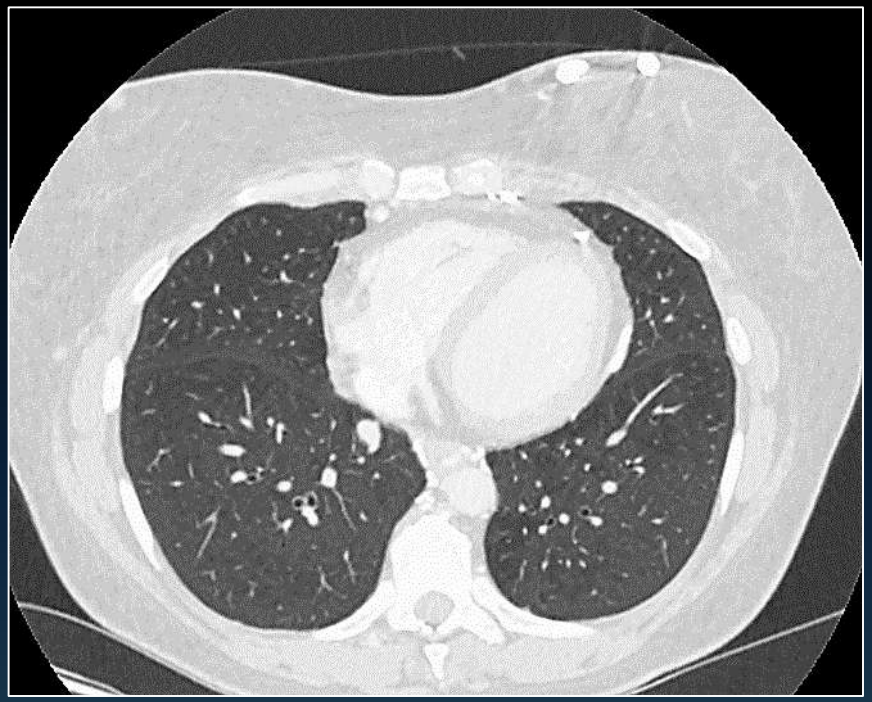

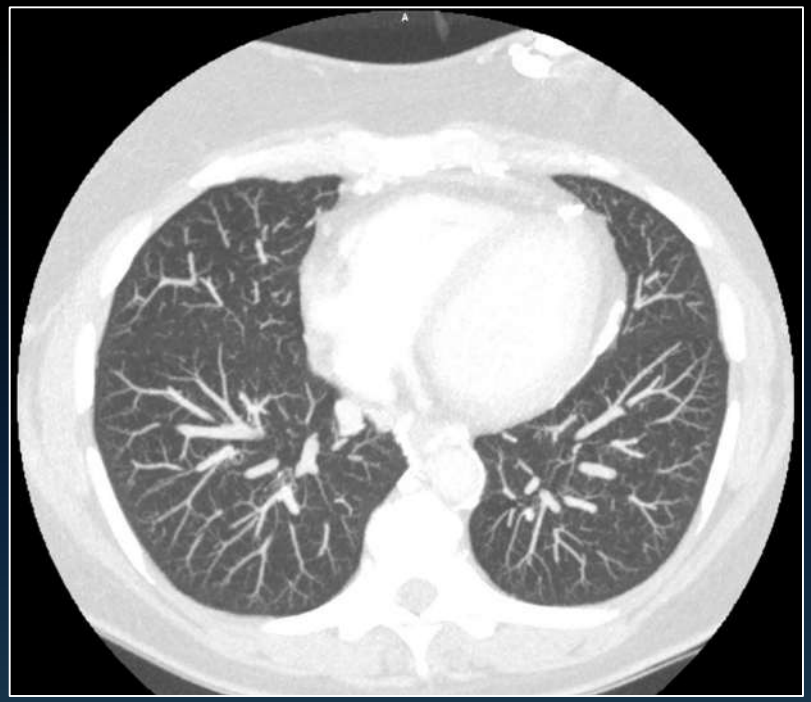

♀ 49 ans – maladie de Behcet

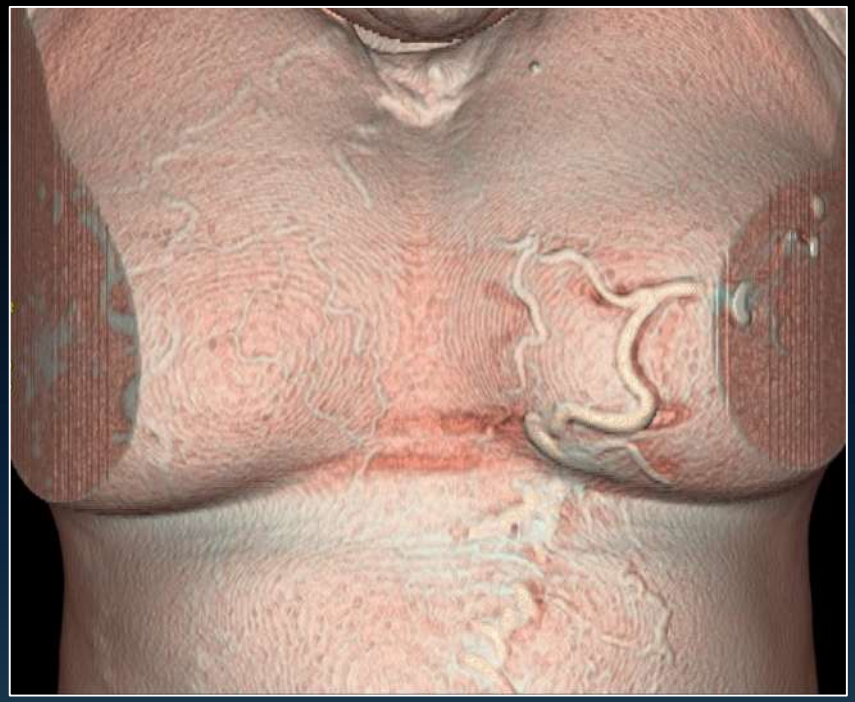

♀ 49 ans – maladie de Behcet

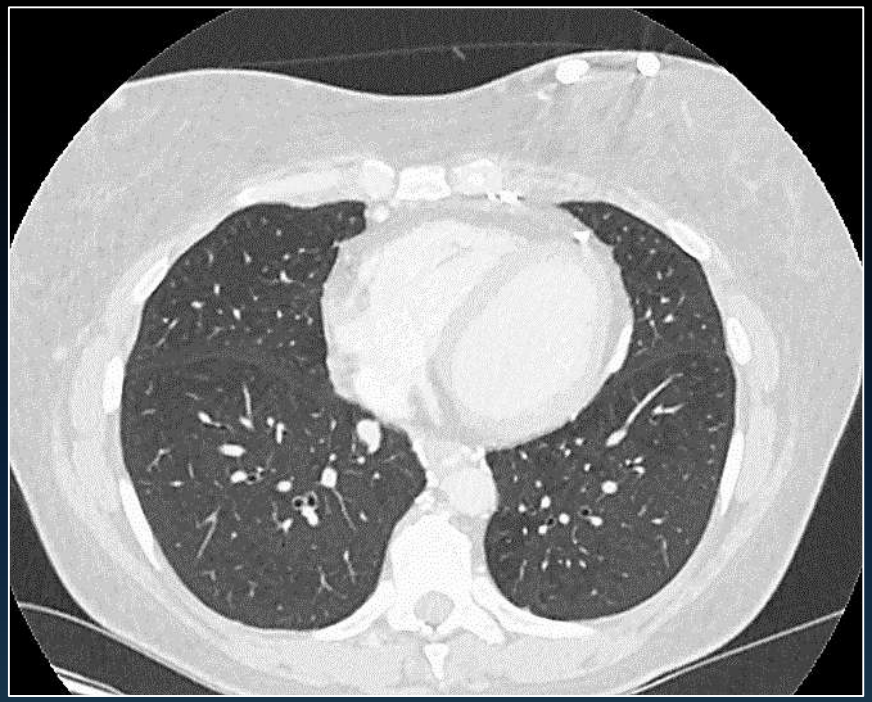

- Plaques pleurales

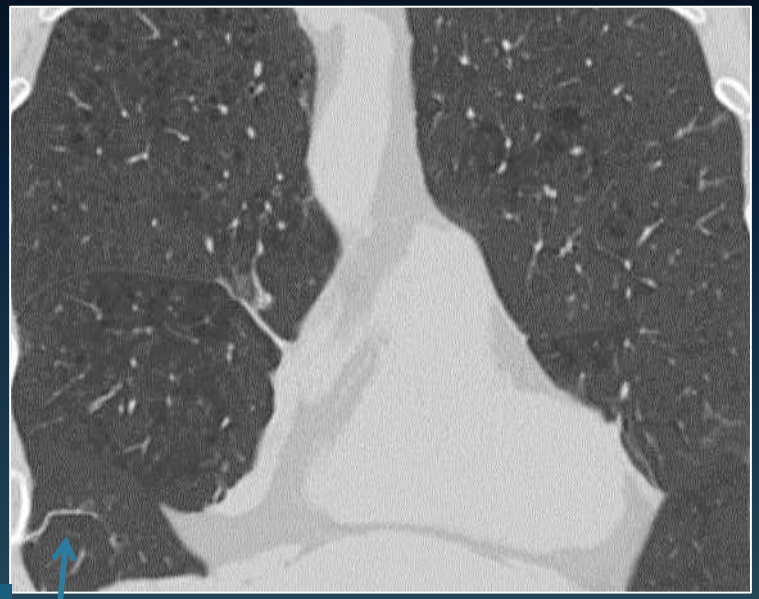

- Bande d’atélectasie

Fistule artério veineuse

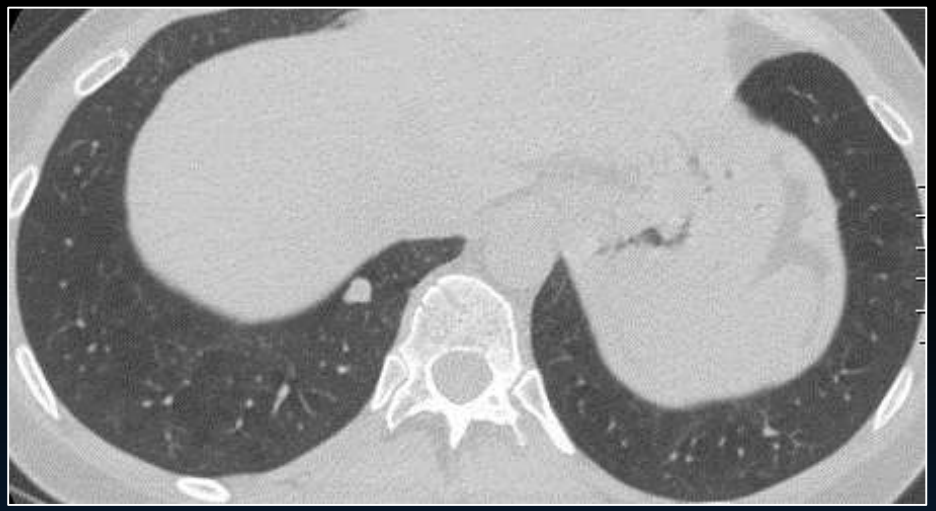

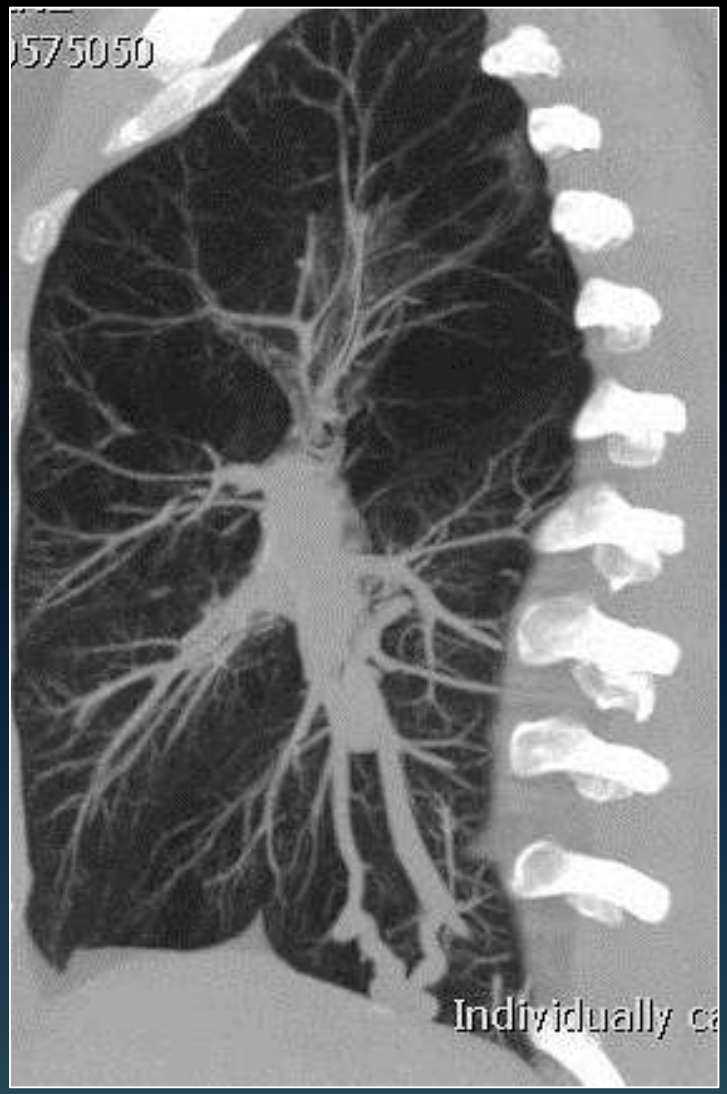

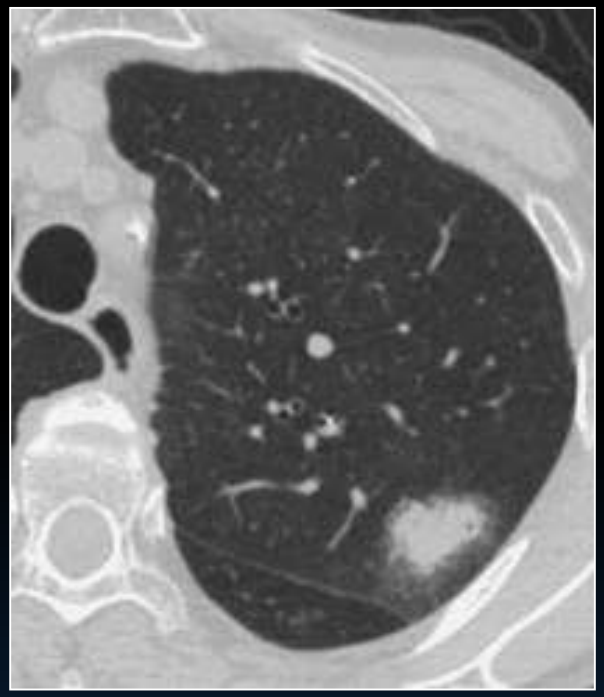
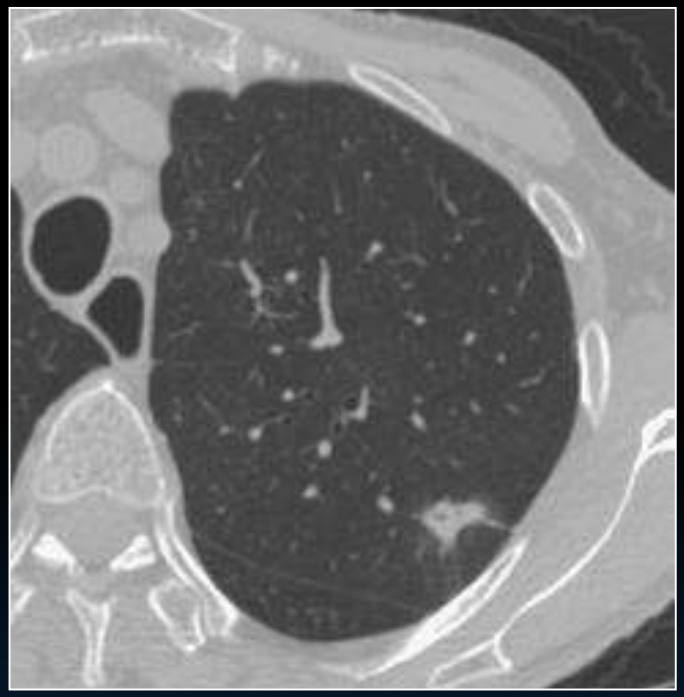
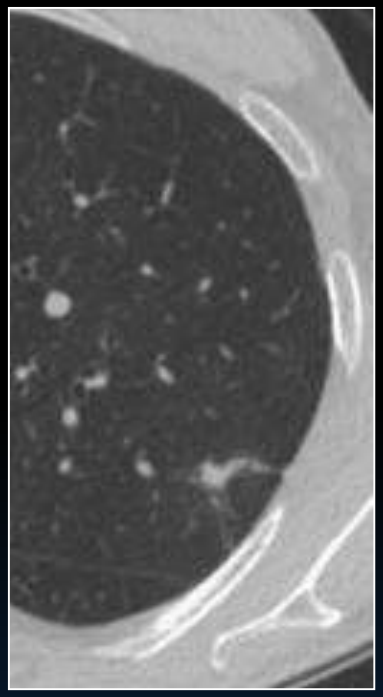

- Eléments prédictifs de régression
  - Nodules mixtes avec large zone solide
  - Contours mal limités
  - Sujet jeune
  - Eosinophilie sanguine

Lee SM. Transient part-solid nodules detected at screening thin-section CT for lung cancer: comparison with persistent part-solid nodules. Radiology 2010

Démarche diagnostique

Fausses images

MAV, anévrisme, impaction mucoïde, atélectasie ronde, plaques pleurales

- Antériorité et stabilité > 2 ans

(nodules solides)



Images bénignes

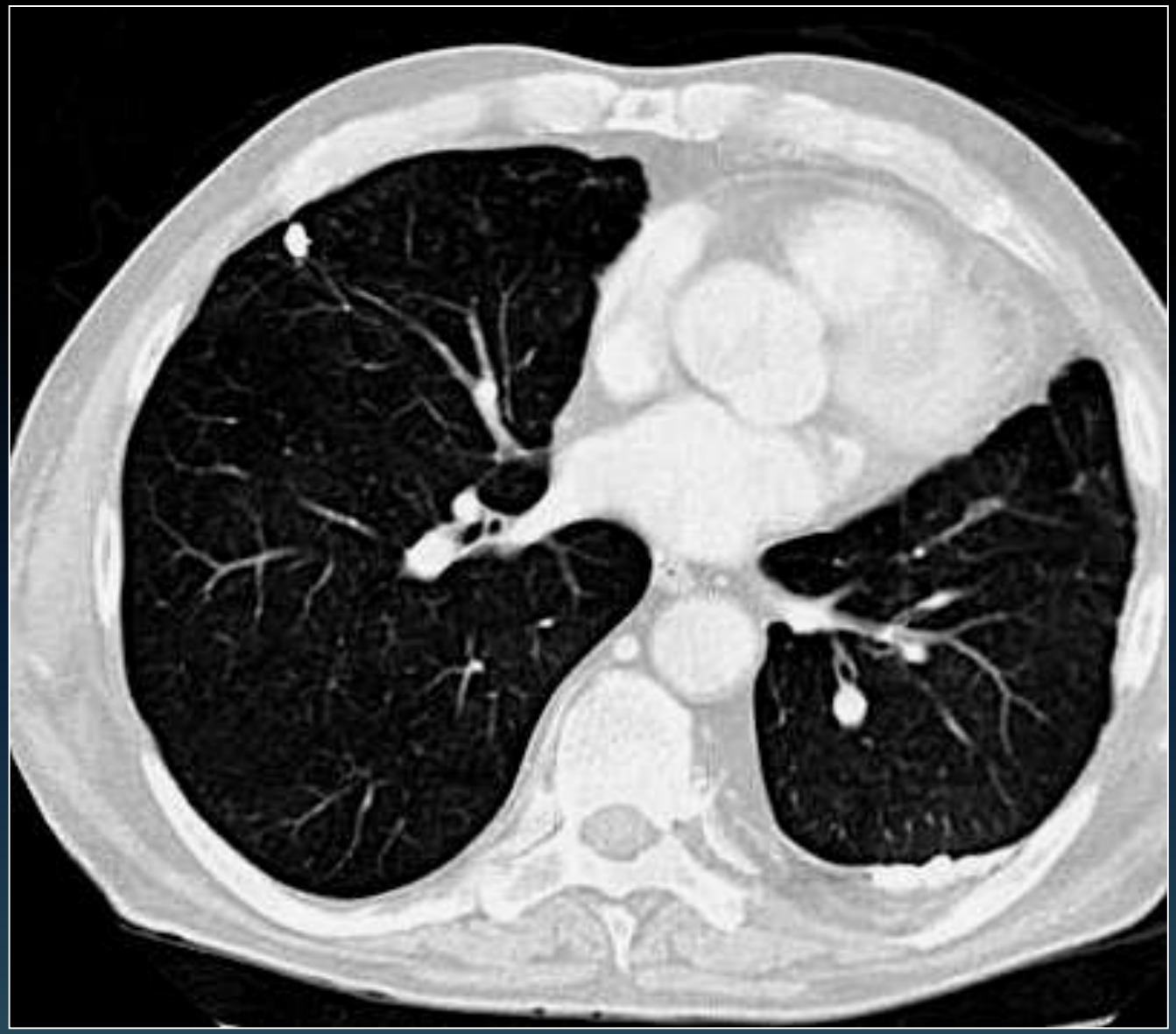

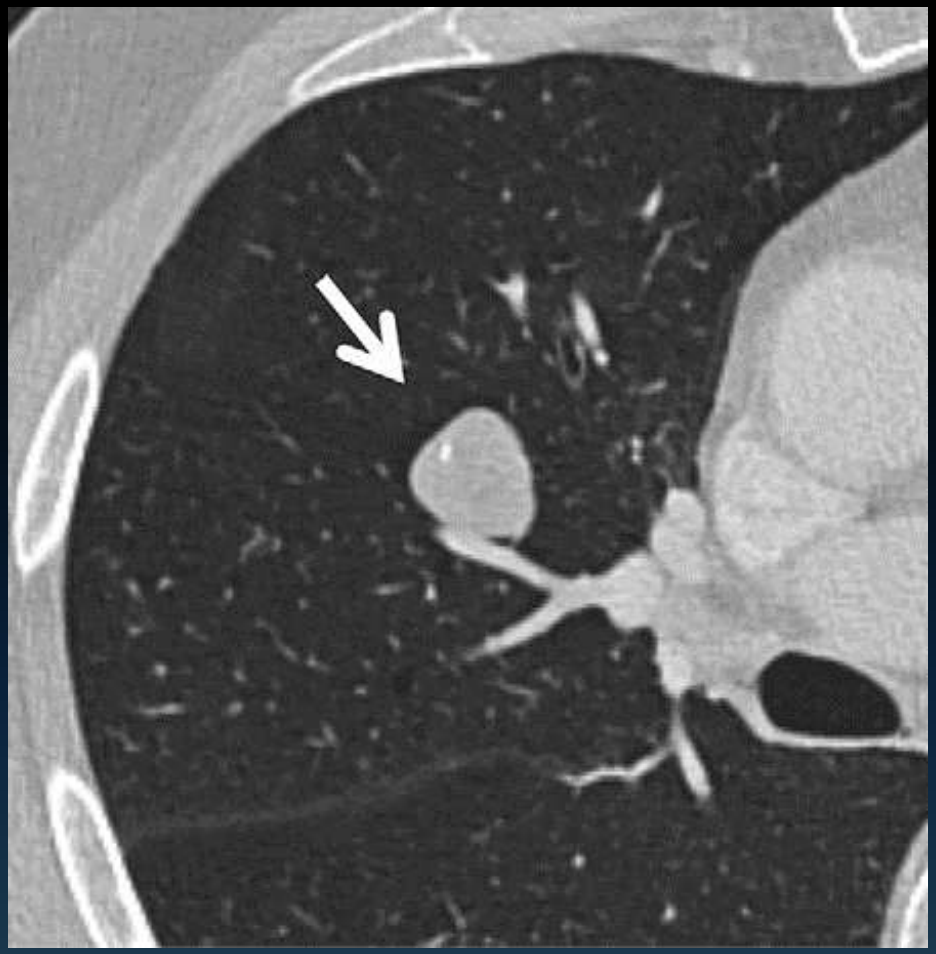

Ganglion parenchymateux

Perifissural Nodules Seen at CT Screening for Lung Cancer[1]

Myeong Radiology 2010

FORME

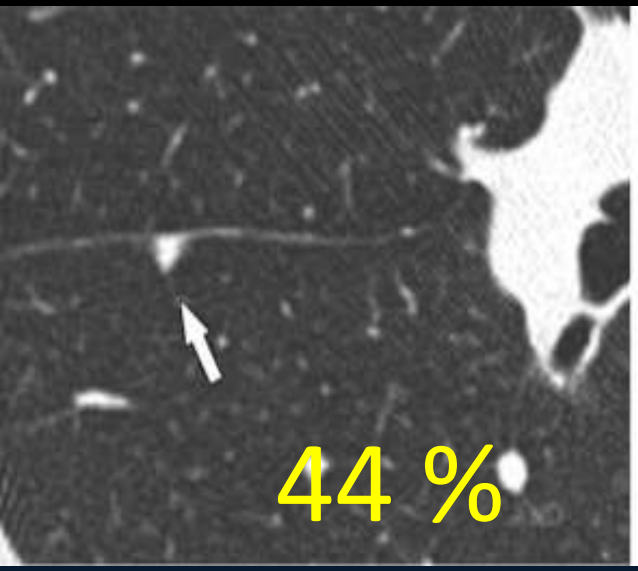

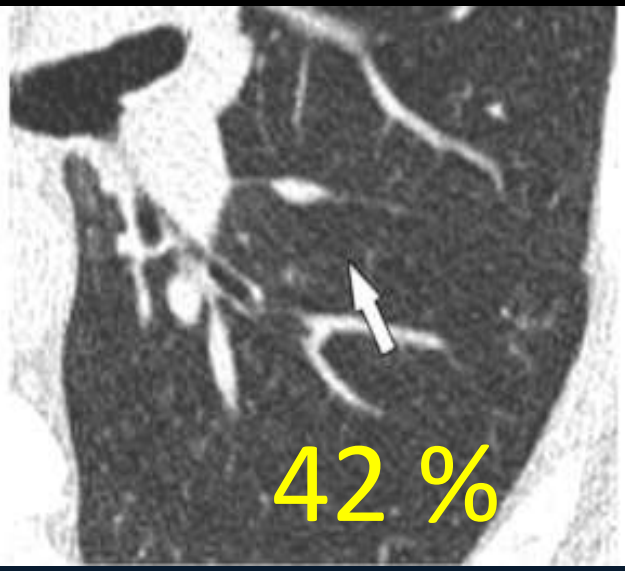

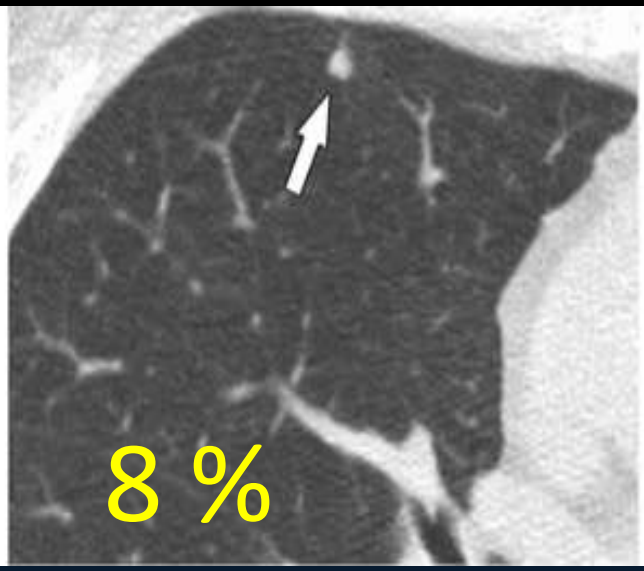

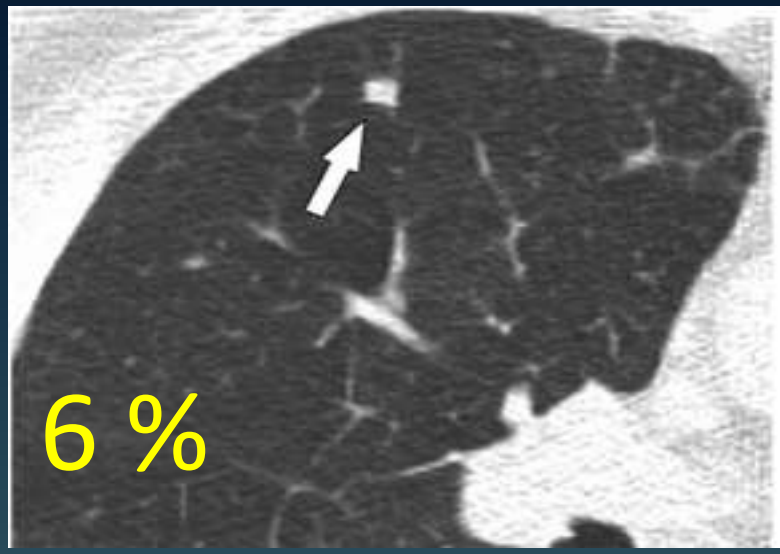

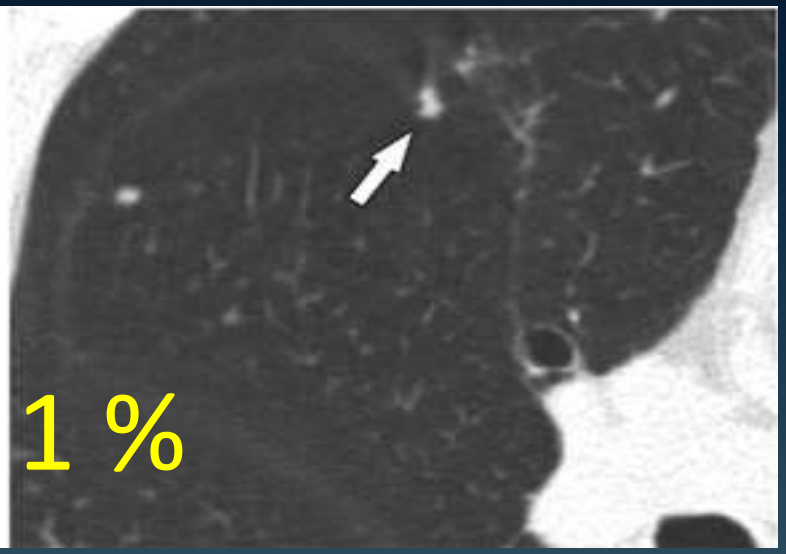

TAILLE

1 mm ↓ **80 %**

5 mm ↓ **19 %**

10 mm ↓ **1 %**

LOCALISATION

Level	
Above carina	23 (10)
At level of carina	15 (6)
Below carina	196 (84)

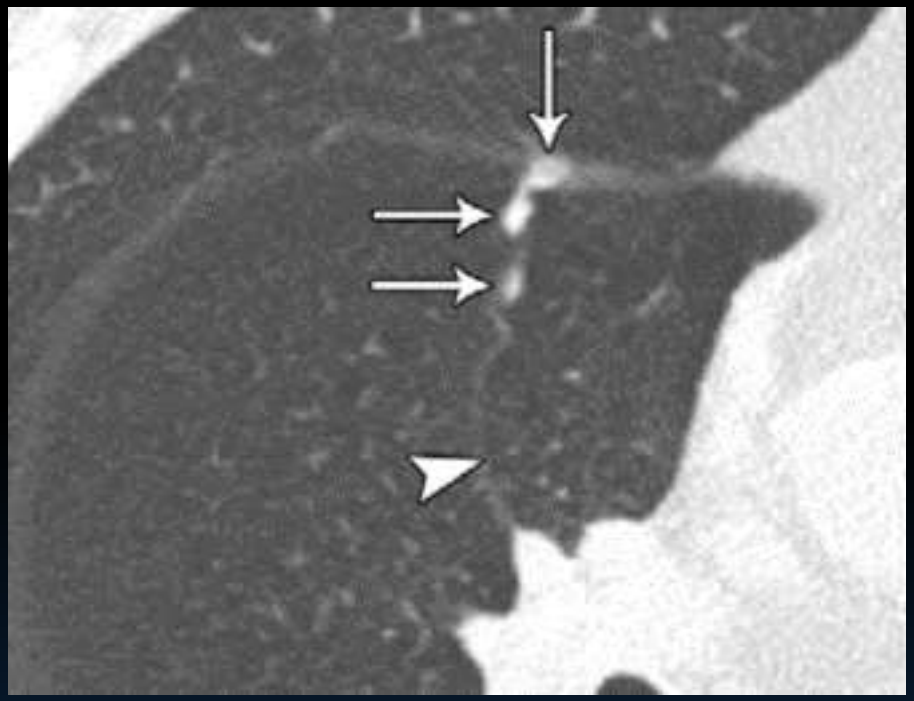

Nombre → Multiples: 48 %

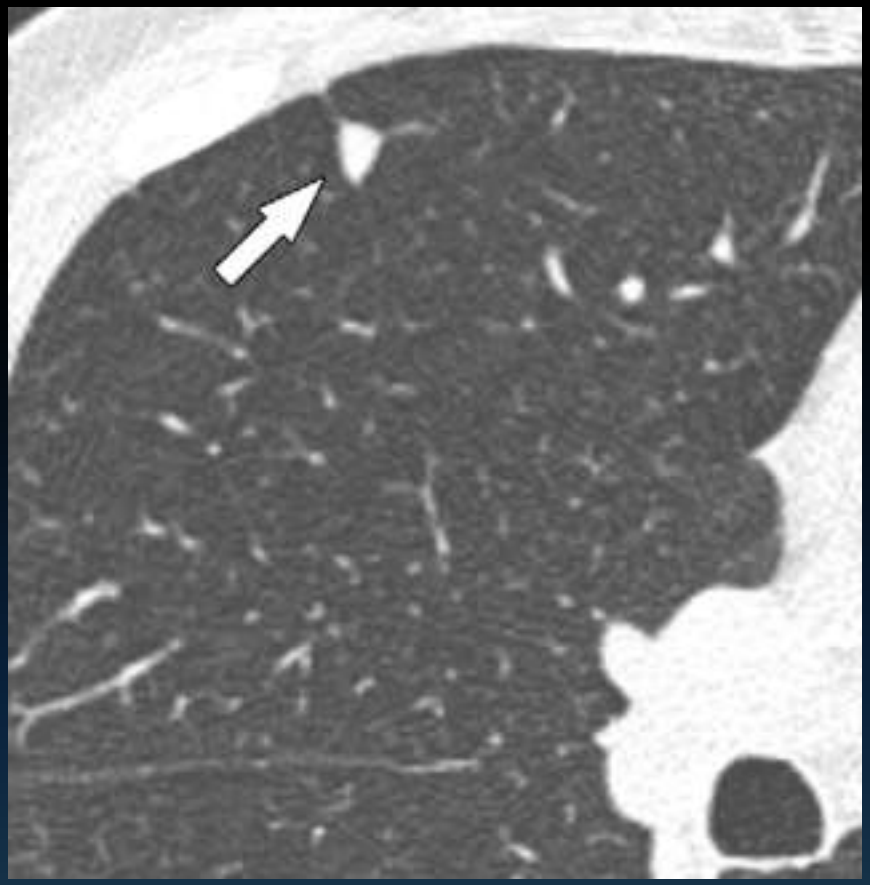

Contact scissural → 73 %

Nodule < 1 cm scissure



< 5 mm

Contours nets

< carène

Connexion septale

BENIN

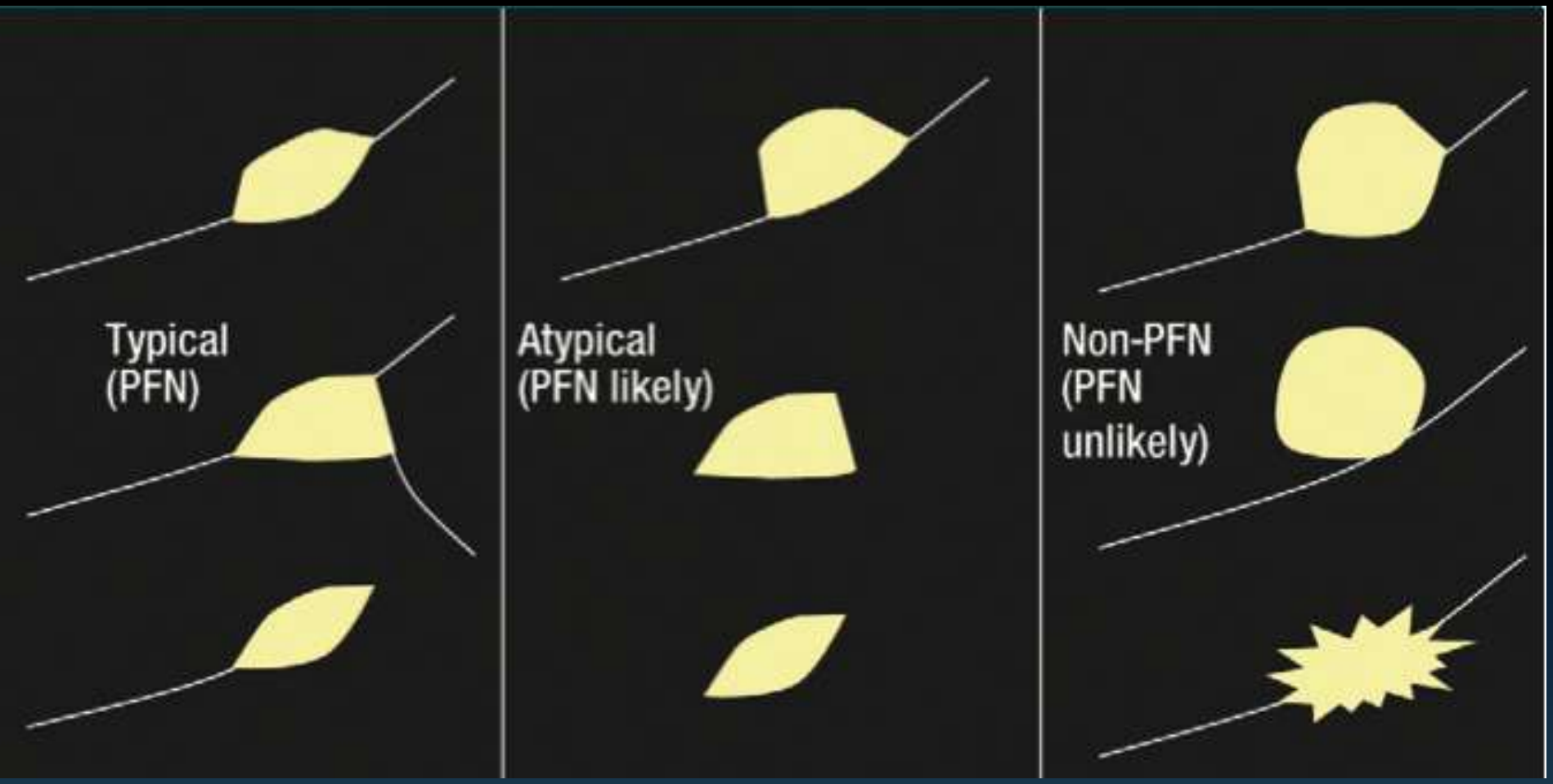
Typical
(PFN)
Atypical
(PFN likely)
Non-PFN
(PFN
unlikely)

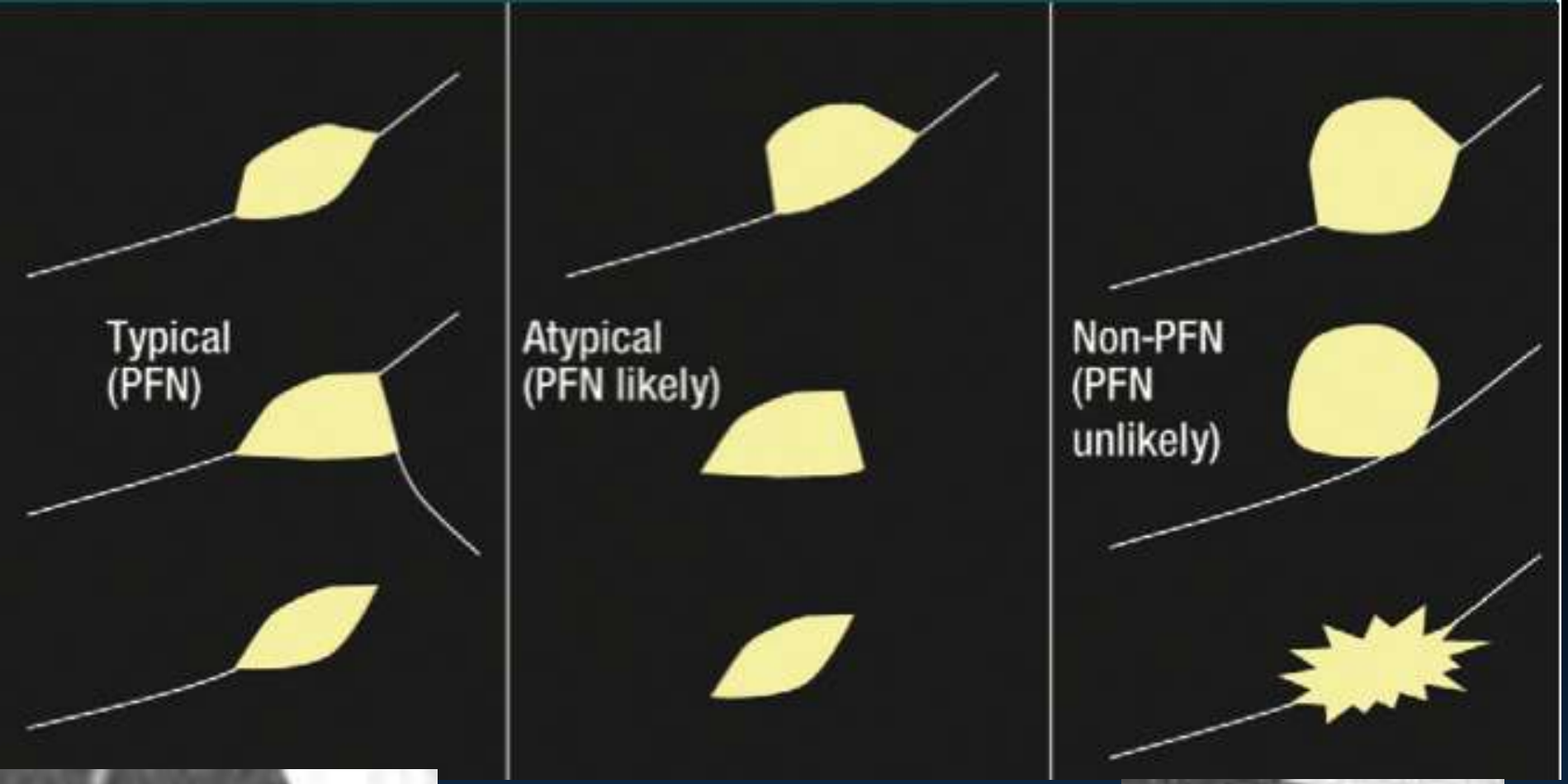
Typical
(PFN)
Atypical
(PFN likely)
Non-PFN
(PFN
unlikely)

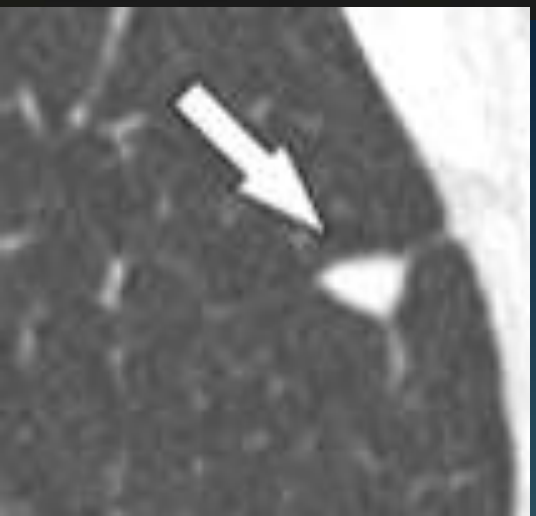

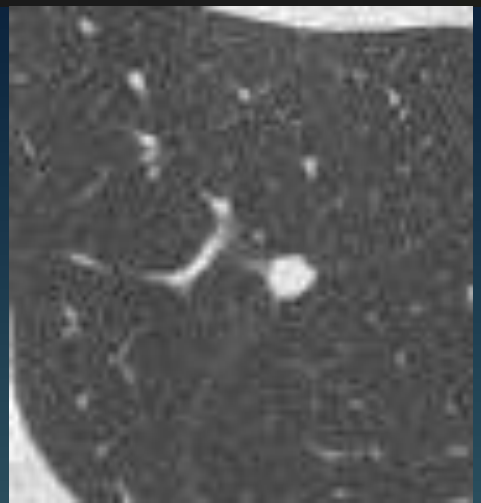

Démarche diagnostique

- **Images bénignes:**
  - Ganglion intrapulmonaire
  - Granulome post infectieux (hors contexte de sarcome)
  - Hamartochondrome
- **SI** présence de tous les critères



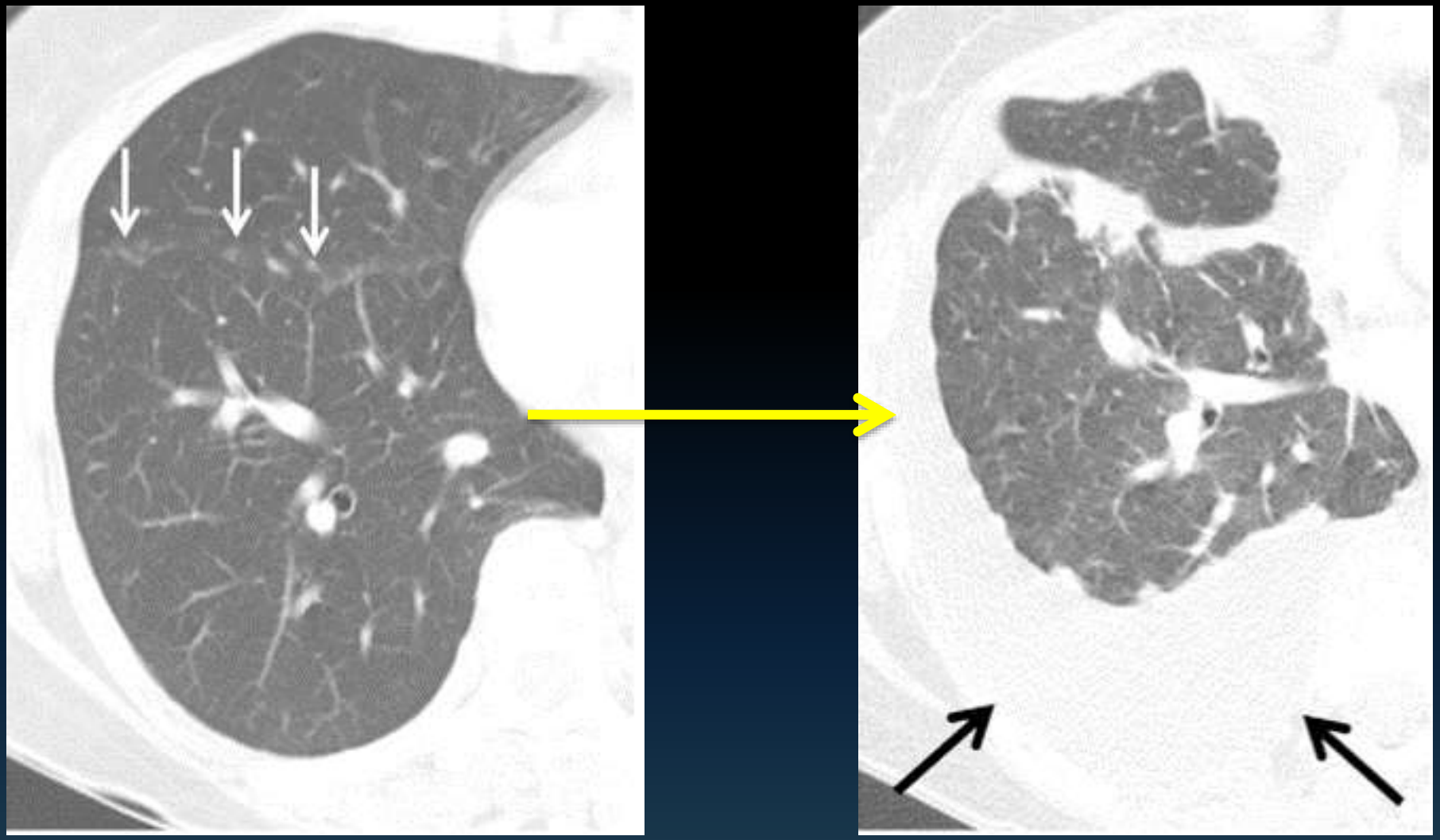

Contexte: Suivi oncologique

Lésions certainement malignes

Démarche diagnostique

- **Lésions certainement malignes**

- Nodule > 20 mm, spiculé, excavé,

Démarche diagnostique

- **Lésions certainement malignes**

- Nodule > 20 mm, spiculé, excavé, clartés aériques

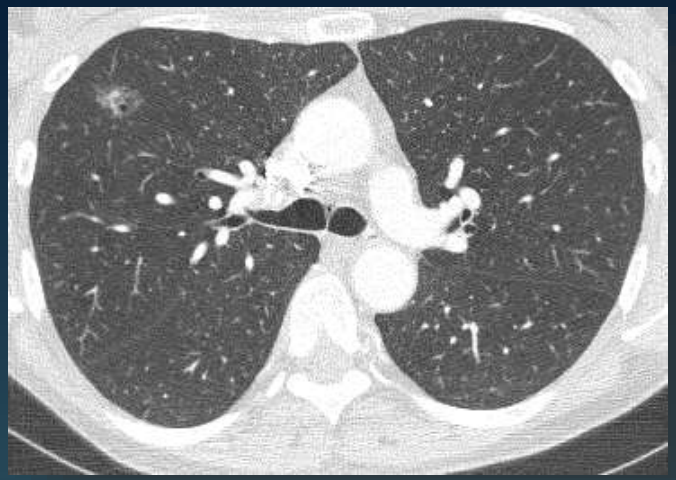



Formes kystiques

ADK à prédominance lépidique avec contingent invasif focal

Démarche diagnostique

- **Lésions certainement malignes**

- Calcifications malignes

- Nodule mixte persistant

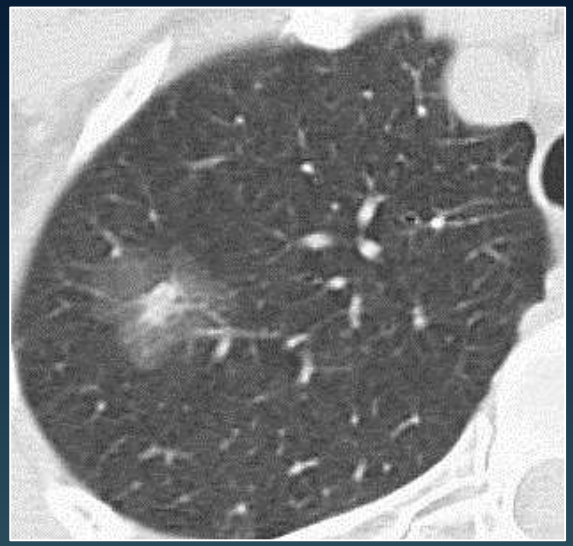

Lésions indéterminées

6 mm < ? < 10 mm

Le nodule pulmonaire

- Problématique
- Démarche diagnostique
  - Suivi oncologique
  - Nodule fortuit
- Surveillance: Recommandations 2017

Guidelines for Management of Incidental Pulmonary Nodules Detected on CT Images: From the Fleischner Society 2017[1]

Radiology

Radiology: Volume 284: Number 1—July 2017

Nodule solide - Fleischner 2017

Taille	Faible risque	Risque élevé
< 6 mm (100 mm3)	Pas de suivi	± 1 an & stop
6-8 mm (100-250 mm3)	6 -12 mois Puis 18-24 mois	6-12 mois Puis 18-24 mois
> 8 mm (>250 mm3)	3 mois / TEP / histologie	

Nodule semi-solide - Fleischner 2017

Taille	Verre dépoli pur	Nodule mixte
< 6 mm	Pas de suivi Si multiples, 3 à 6 mois puis 2 et 4 ans	
≥ 6 mm	6-12 puis tous les 2 ans jusqu'à 5 ans	3 à 6 mois Portion dense < 6 mm contrôle annuel pendant 5 ans Portion dense ≥ 6 mm : Histologie

Verre dépoli pur solitaire < 6mm

- Pas de surveillance

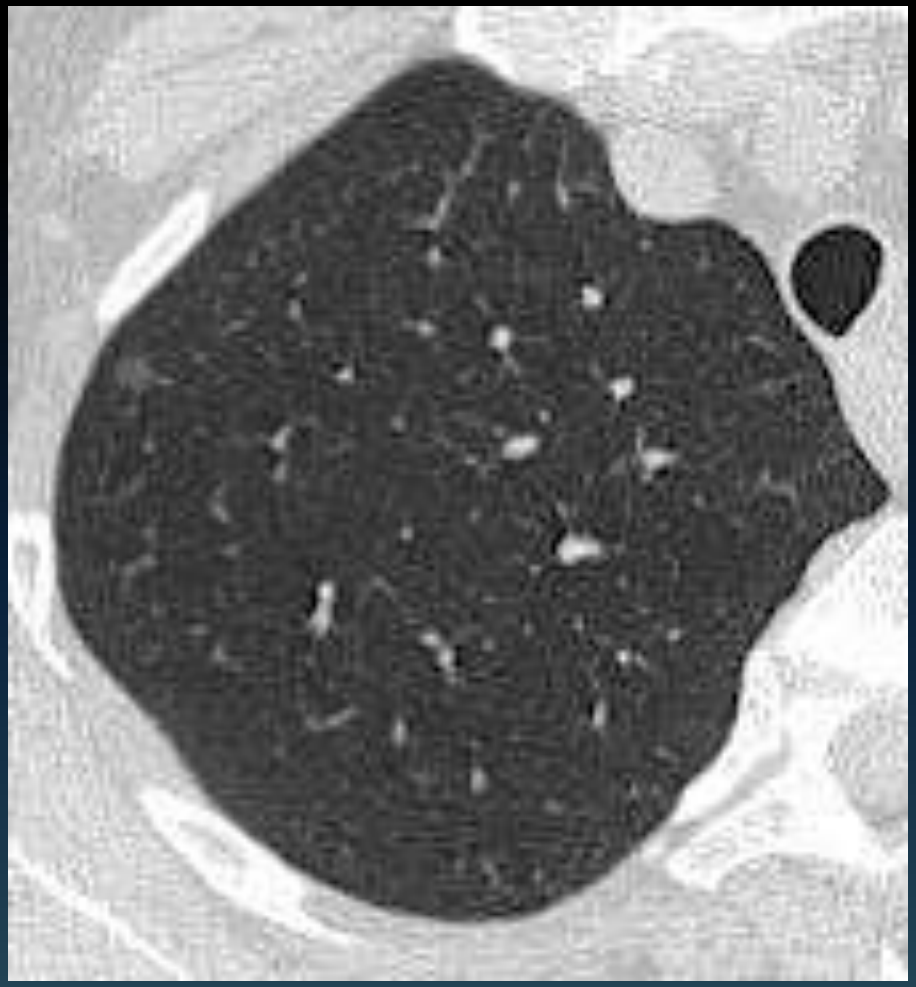

Verre dépoli pur solitaire ≥ 6mm

- TDM entre 6 et 12 mois (persistance ?)

puis tous les 2 ans jusqu'à 5 ans

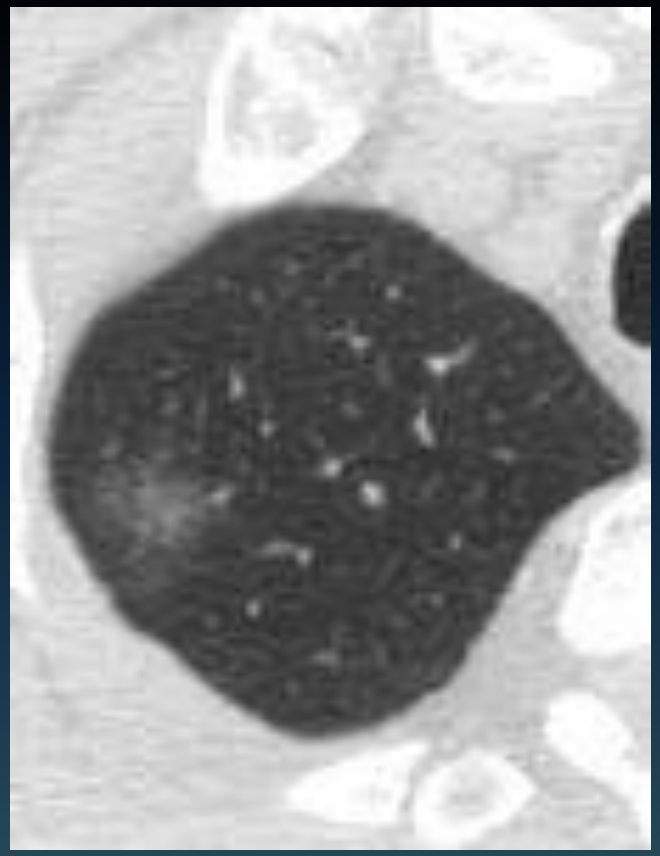

Nodule solitaire mixte

TDM à 3 mois

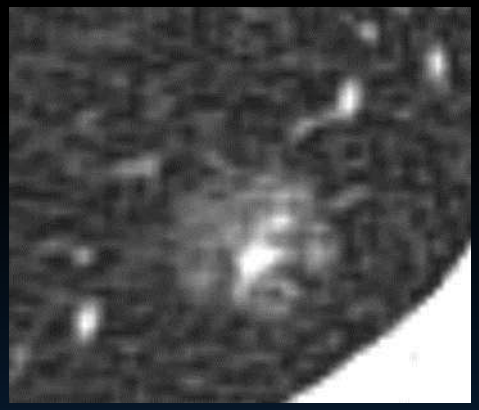



< 6 mm

TDM à 1, 2, 3 ans…

≥ 6 mm

Vérification histologique

Nodule solitaire mixte

TDM à 3 mois

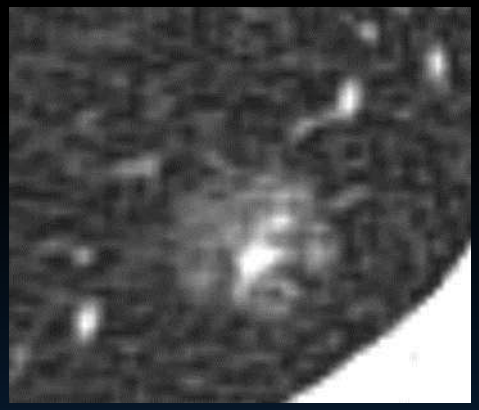



< 5 mm

TDM à 1, 2, 3 ans…

≥ 5 mm

Vérification histologique,
Rôle du radiologue

Ronald L. Eisenberg, MD
Alexander A. Bankier, MD
Philip M. Boiselle, MD

Compliance with Fleischner Society Guidelines for Management of Small Lung Nodules: A Survey of 834 Radiologists[1]

Radiology: Volume 255: Number 1—April 2010

Of 834 respondents (response rate, 11.9%), 649 (77.8%) were aware of the Fleischner Society guidelines and 490 (58.8%) worked in practices that employed them or similar guidelines. Management selections were consistent with the Fleischner guidelines in 34.7%–60.8% of responses

Among survey respondents, there was high awareness and adoption of the Fleischner guidelines, but radiologists showed varying degrees of conformance with these recommendations. Future efforts are necessary to bridge the gap between awareness and implementation of these evidence-based guidelines.

[Original Research **Lung Cancer**]

CHEST

Management of Pulmonary Nodules by Community Pulmonologists

A Multicenter Observational Study

Nichole T. Tanner, MD, MSCR; Jyoti Aggarwal, MHS; Michael K. Gould, MD; Paul Kearney, PhD; Gregory Diette, MD, MHS; Anil Vachani, MD; Kenneth C. Fang, MD; and Gerard A. Silvestri, MD

PODCAST

Radiology

Observer Variability for Classification of Pulmonary Nodules on Low-Dose CT Images and Its Effect on Nodule Management[1]

- Pulmonary nodule classification according to current guidelines has substantial inter- and intraobserver variability (mean κ, 0.51 and 0.57, respectively) on low-radiation-dose CT scans.
- Inter- and intraobserver variability is in almost 90% related to the definition and measurement of a solid component in pulmonary nodules.
- Inter- and intraobserver variability in nodule classification on low-radiation-dose CT scans results in potentially different nodule management strategies.

- 8 radiologues:
4 membres de la Fleischner society
2 radiologues impliqués dans Nelson
2 Radiolgues généralistes avec un intérêt pour l'imagerie thoracique

Les limites et l’avenir ?

Limites des mesures manuelles du diamètre

Ne détectent pas les croissances asymétriques

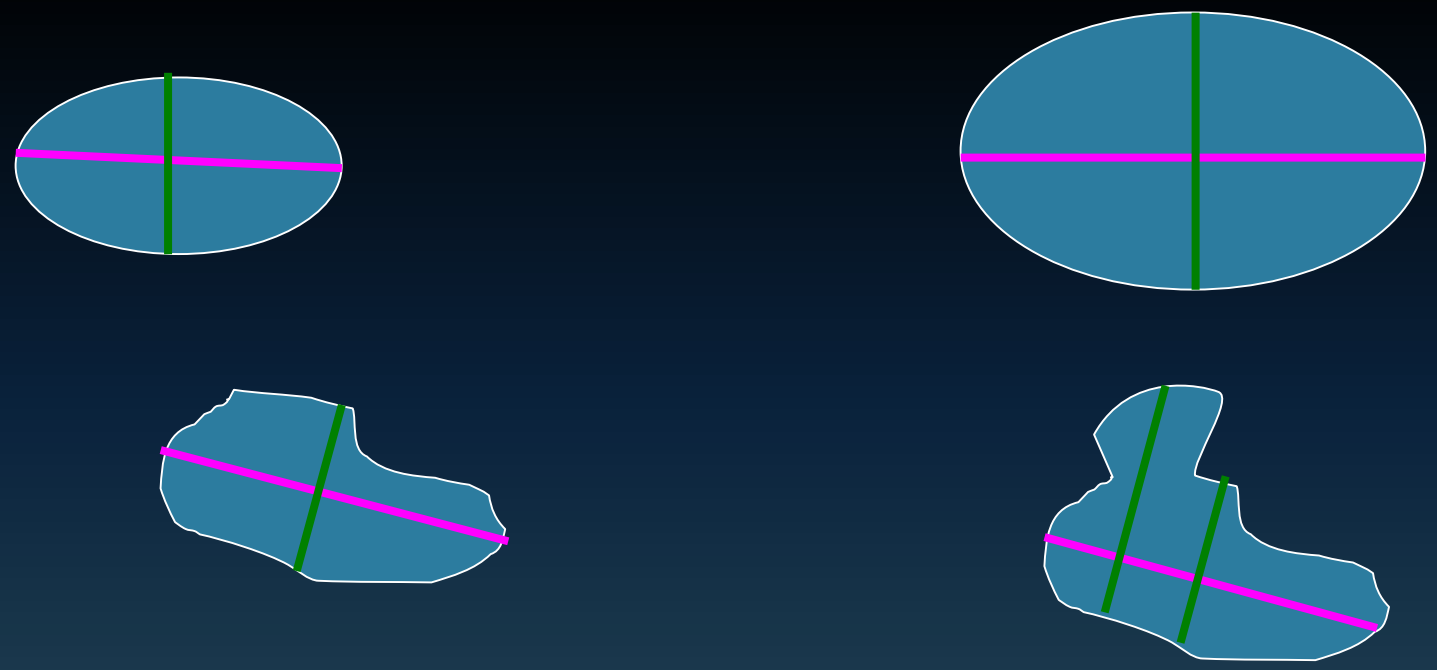

[1]Yankelevitz DF. Radiology 1999

Limites des mesures manuelles du diamètre

Erreur de mesure 2 : 1.3 à 1.7 mm

- Analyse volumique

  Nodule = sphère **Doublement du volume Augmente de 26% diamètre**

5 mm



6.25 cm

variabilité mesure de l'ordre de l'augmentation du diamètre d'un nodule de 5 mm qui double son volume

Revel MP. Radiology.2004

NS 423 mm^3

S 1152 mm^3

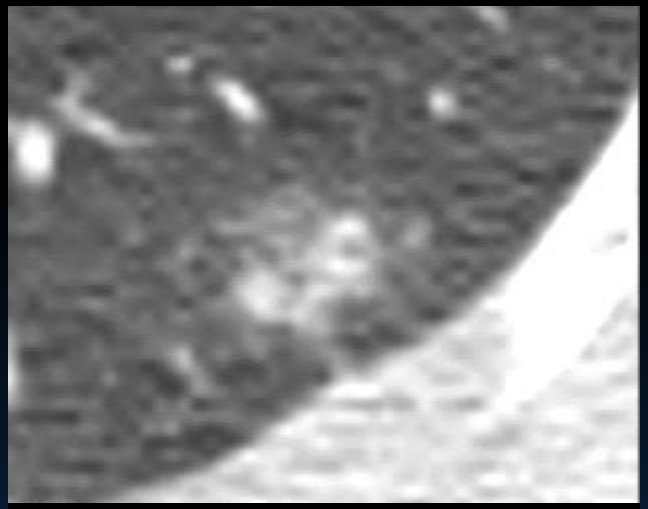

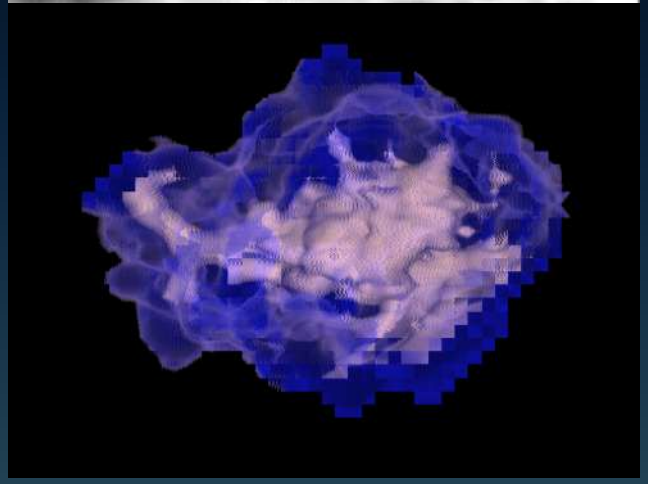

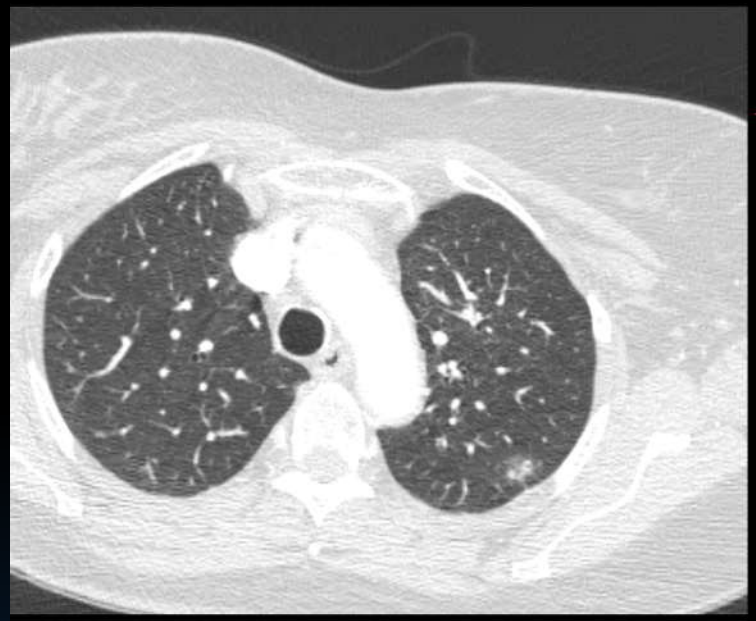

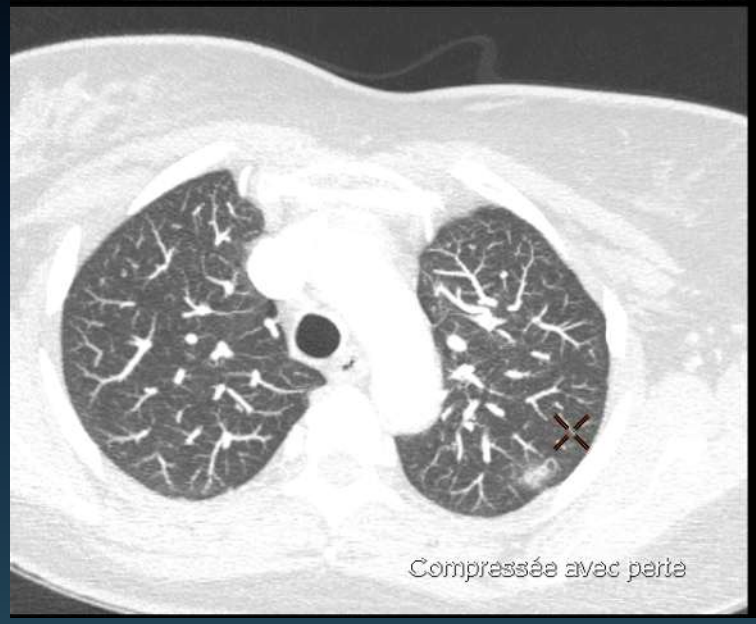

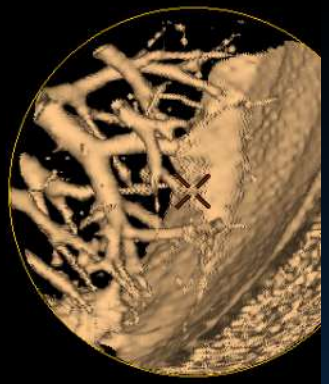

	2003	2005	2008	2010
		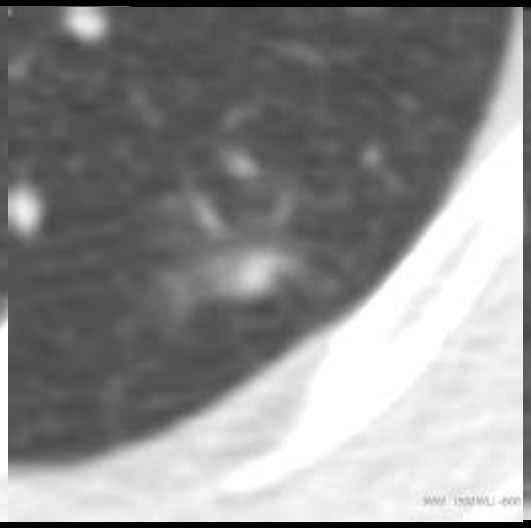	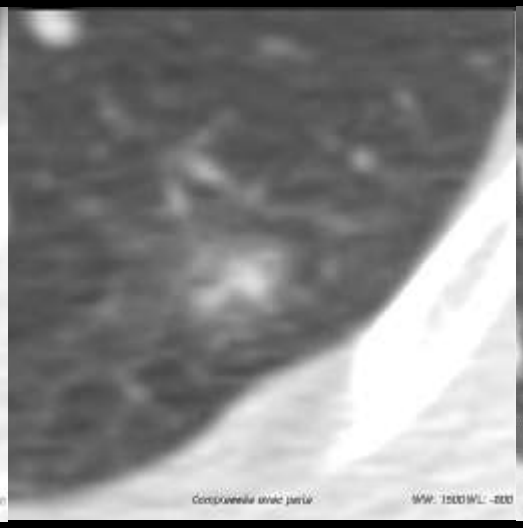	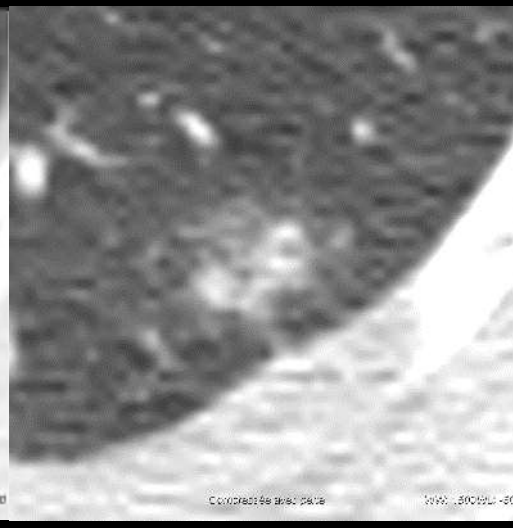
	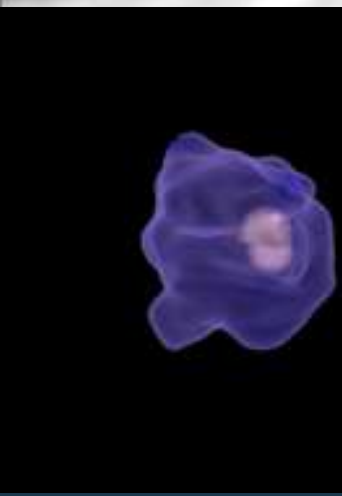	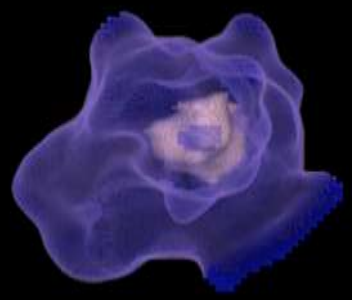	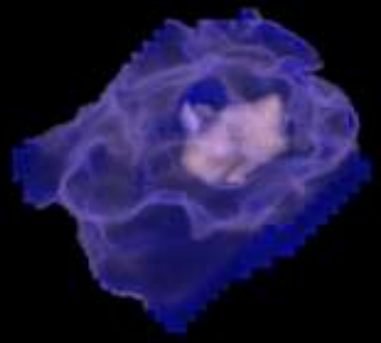	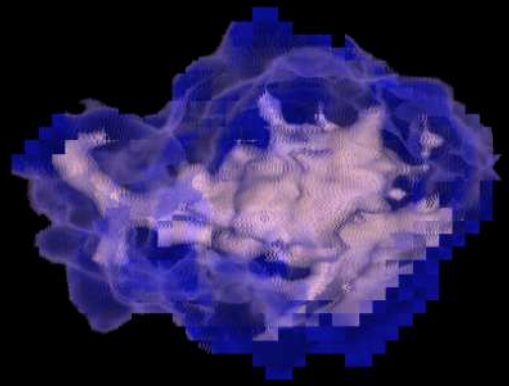
NS	191 mm^3	428 mm^3	541 mm^3	423 mm^3
S	20 mm^3	66 mm^3	179 mm^3	1152 mm^3

Validités des mesures de volume

- **Même nodule même Jour 8-15%**
- **Ecart type jusqu'à 25%**

- **Changement de vol < 25% = bruit**

Godman AJR 2006 Ravenel Radiology 2008

Suivi sur le volume

Etude Nelson

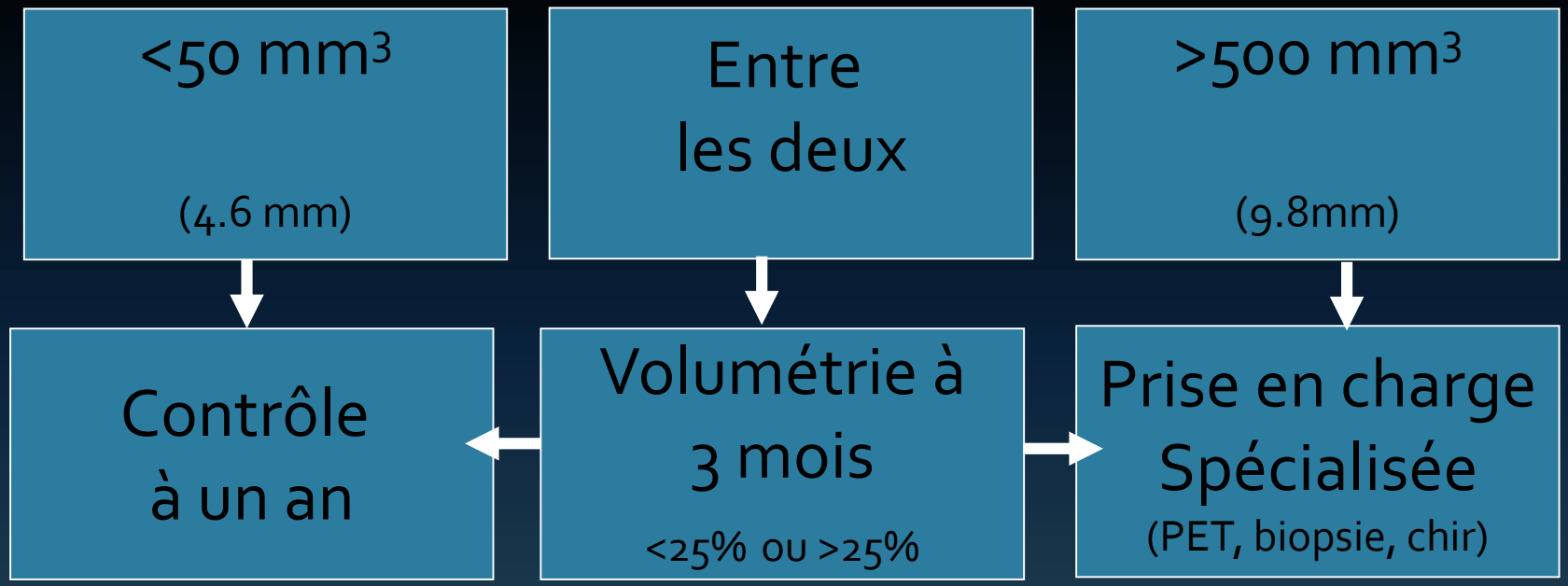

Conclusion

- ✓ Des diagnostics de bénignité
- ✓ Simplification des recommandations pour la surveillance des nodules fortuits
- ✓ Des logiciels pour la détection précoce des nodules évolutifs